疾患知識のオントロジー事例報告集

■ 事例

以下、TOF エディタにて、疾患の異常状態連鎖を表示した例（7 診療科領域の代表例１０例ずつ）を示す。黄色の部分は疾患の定義に必要な「疾患定義連鎖」、より濃い色（オレンジ）は「上位疾患から継承された疾患定義連鎖」、白い部分は、「派生連鎖＝定義には含まれないがその疾患で見られうる異常状態連鎖」を表す。

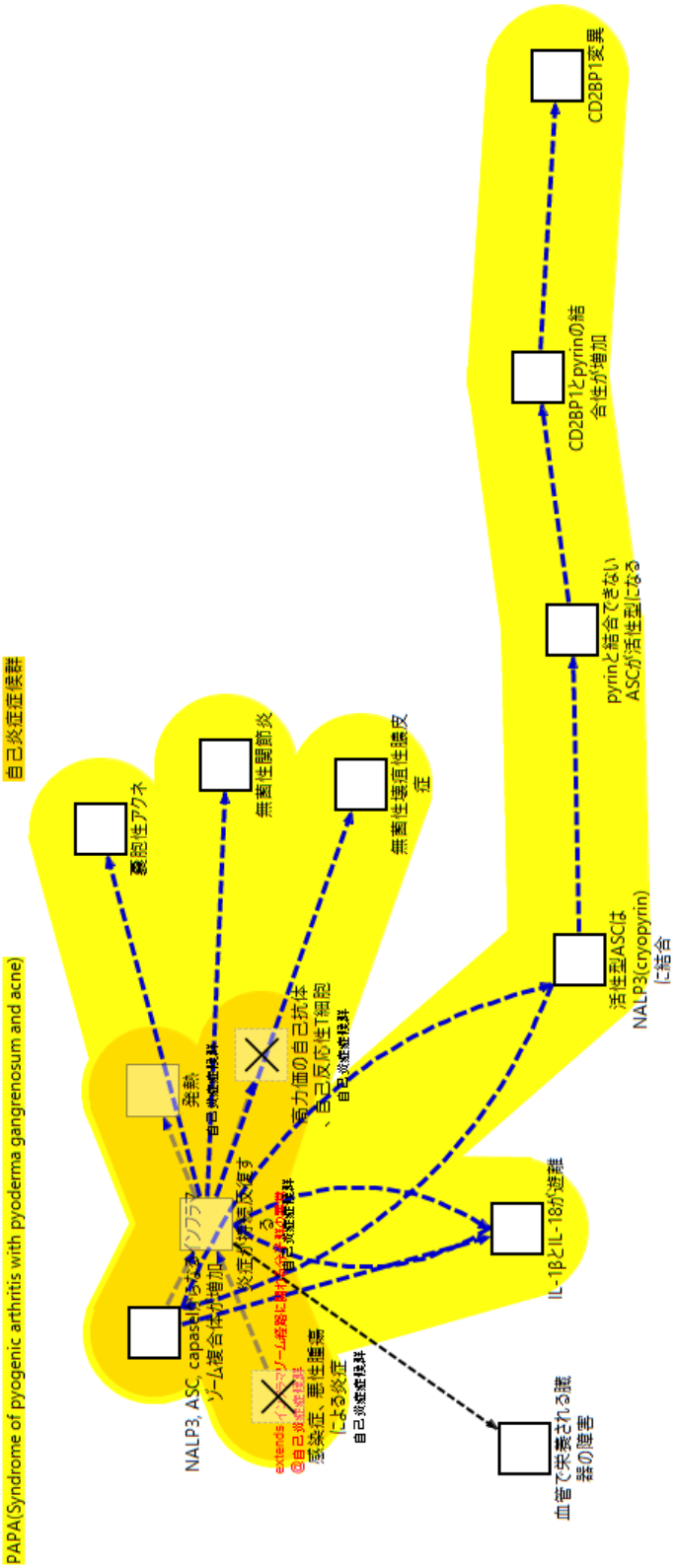
PAPA(Syndrome of pyogenic arthritis with pyoderma gangrenosum and acne)
自己炎症症候群
NALP3, ASC, capase1を含むインフラ
ソーム複合体が増加
炎症が亢進する
発熱
extends
@自己炎症症候群
感染症、悪性腫瘍
による炎症
自己炎症症候群
自己炎症症候群
自己炎症症候群

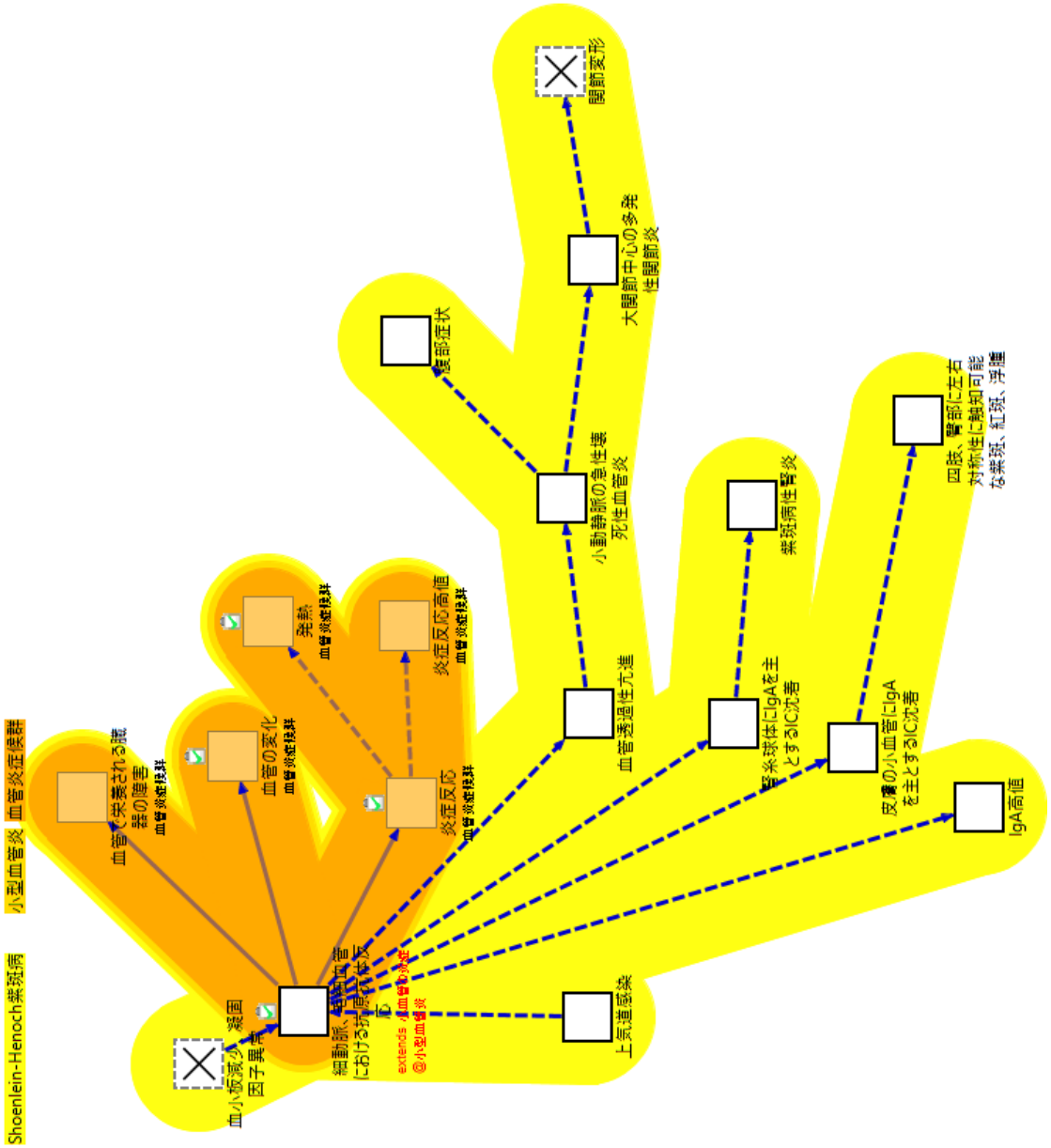

Figure 2. アレルギーリウマチ内科:Shoenlein-Henoch 紫斑病

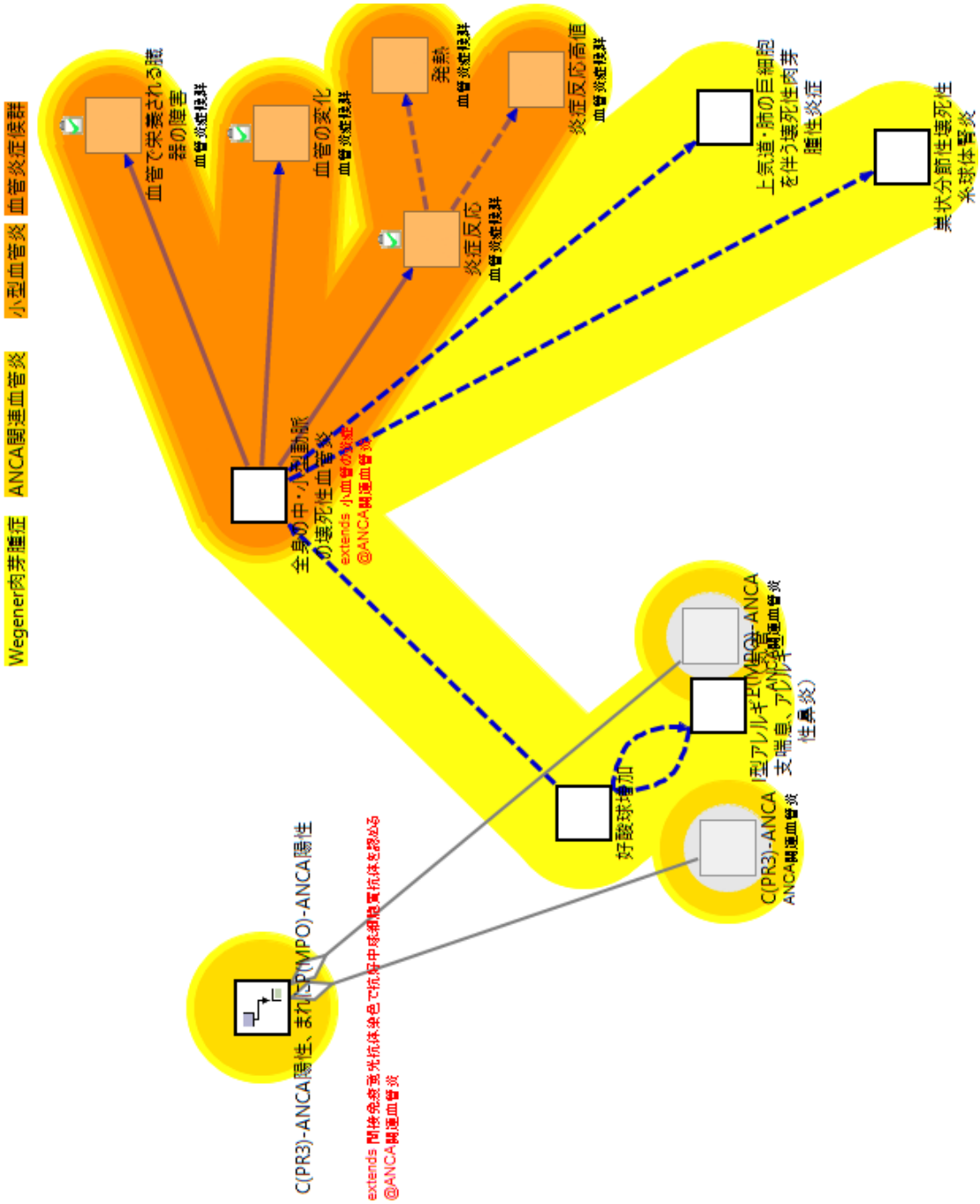

Figure 3. アレルギーリウマチ内科:Wegener 肉芽腫症

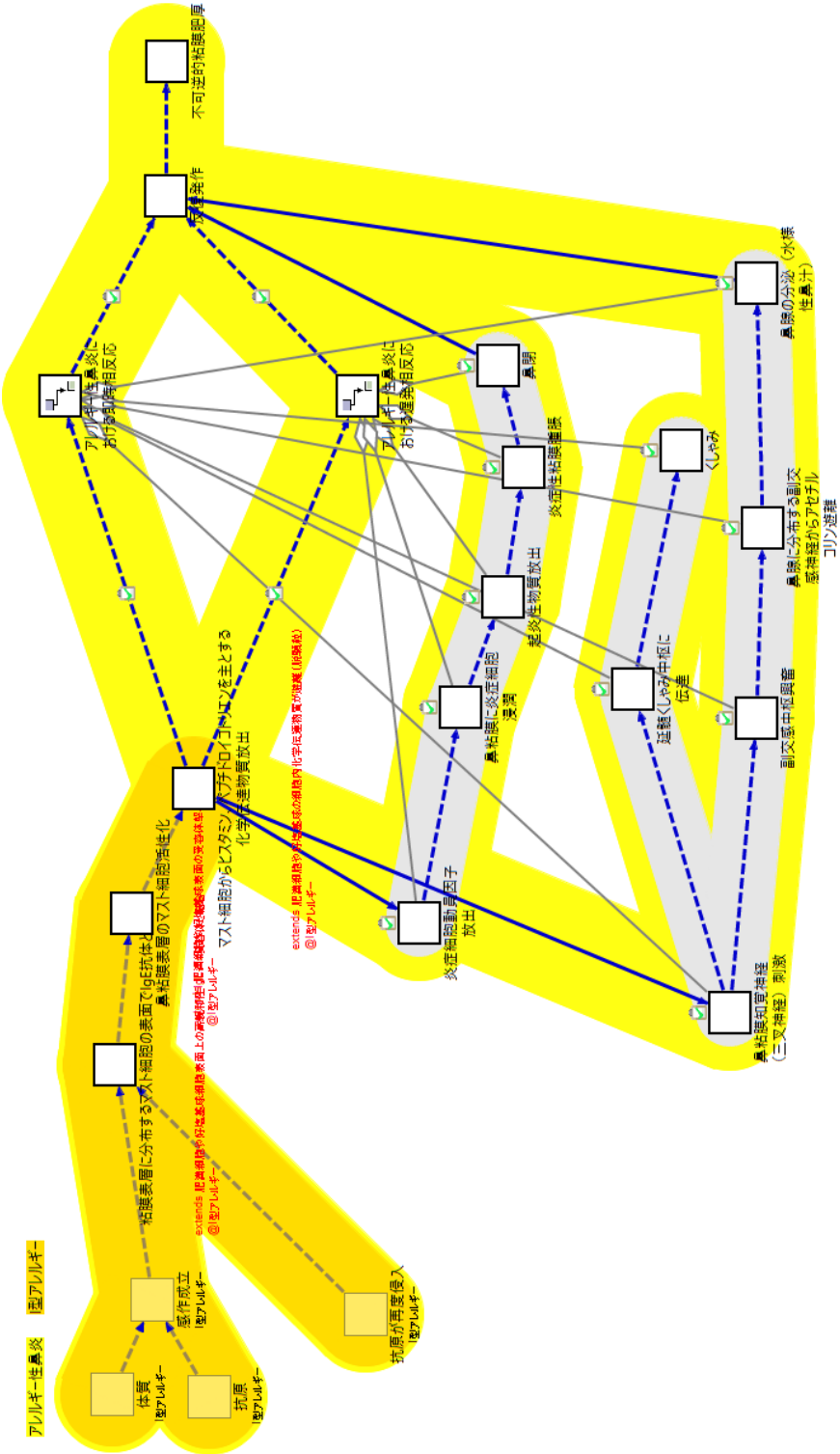

Figure 4. アレルギーリウマチ内科:アレルギー性鼻炎

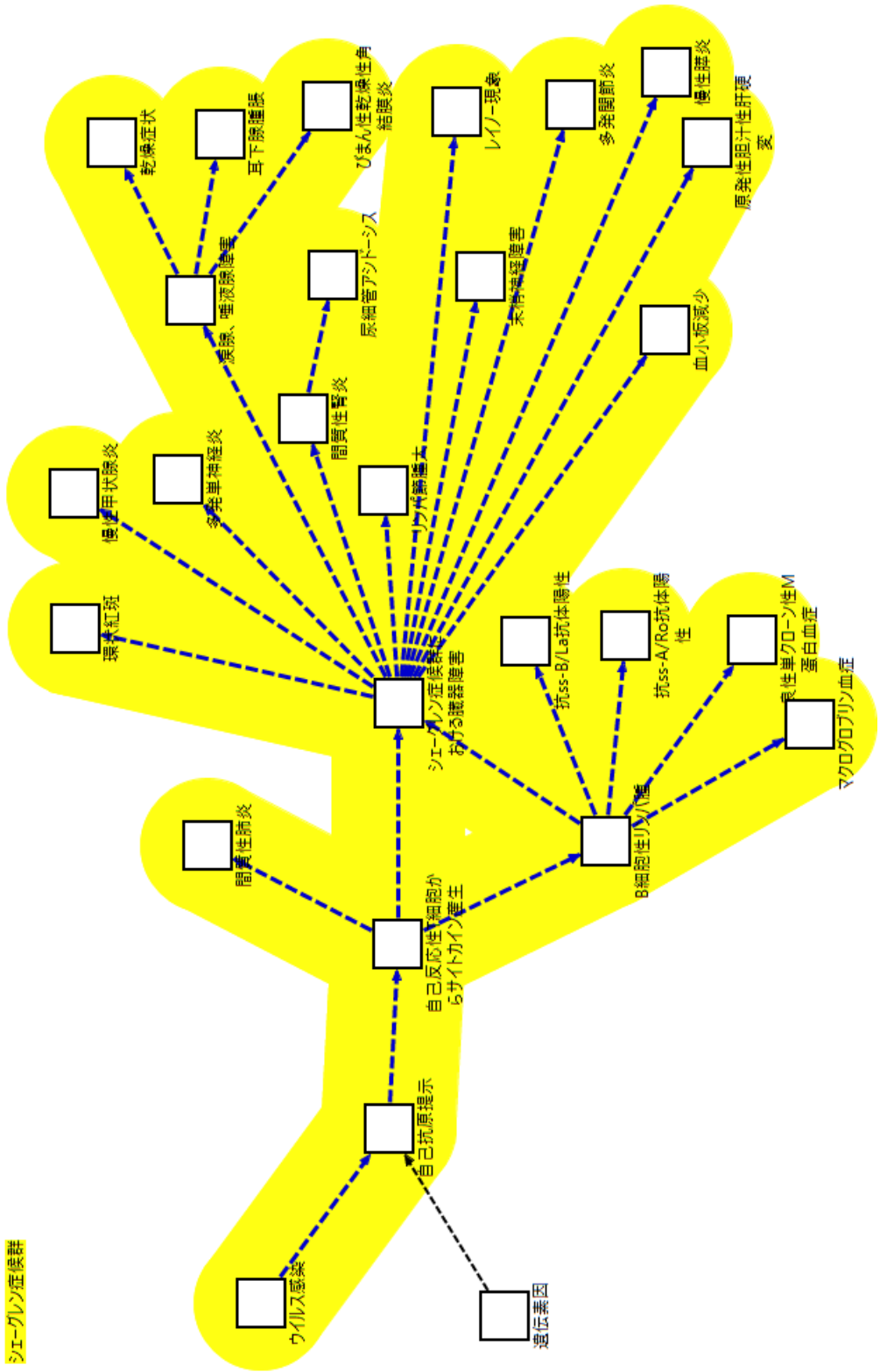

Figure 5. アレルギーリウマチ内科:シェーグレン症候群

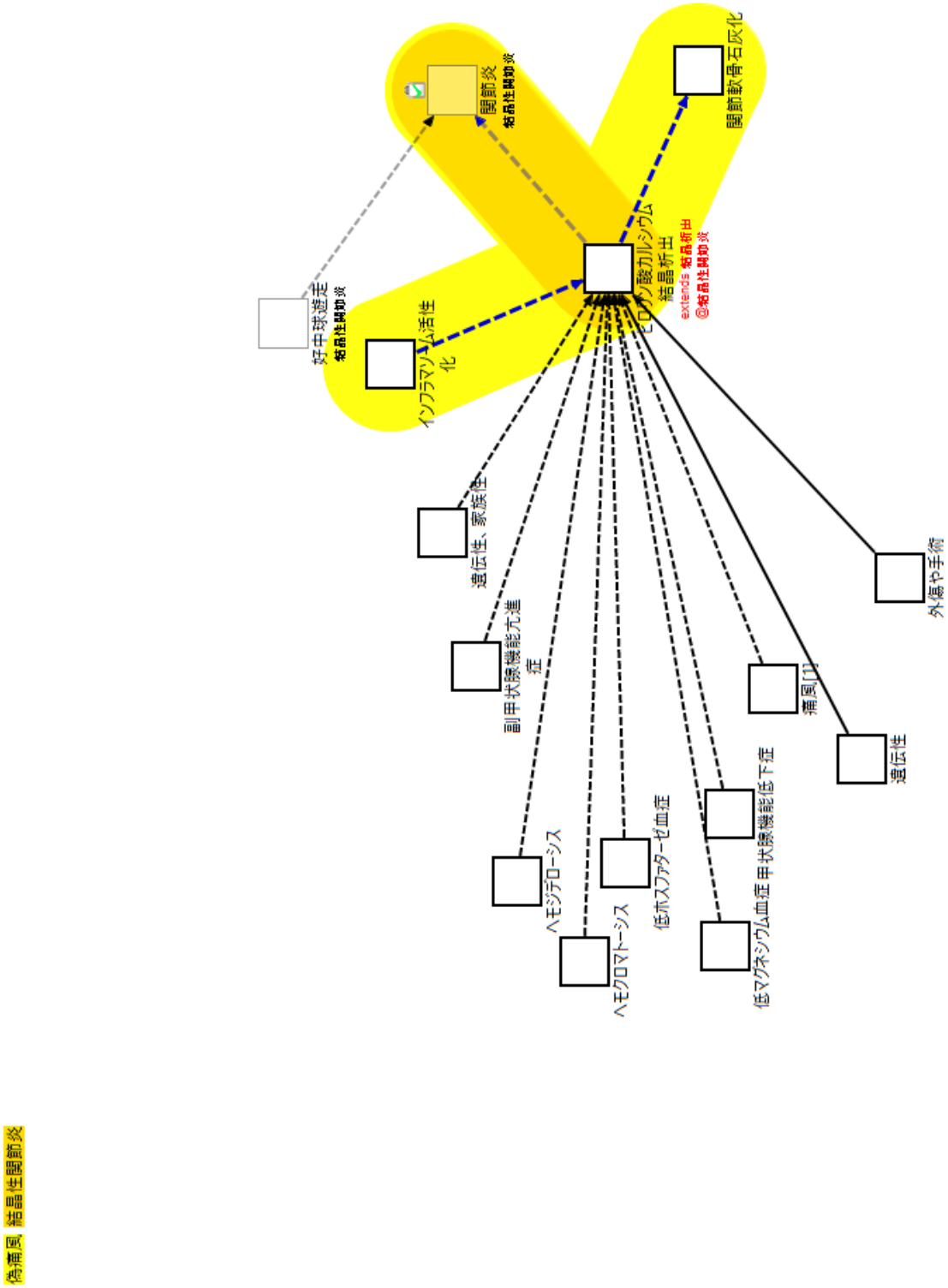

Figure 6. アレルギーリウマチ内科:偽痛風

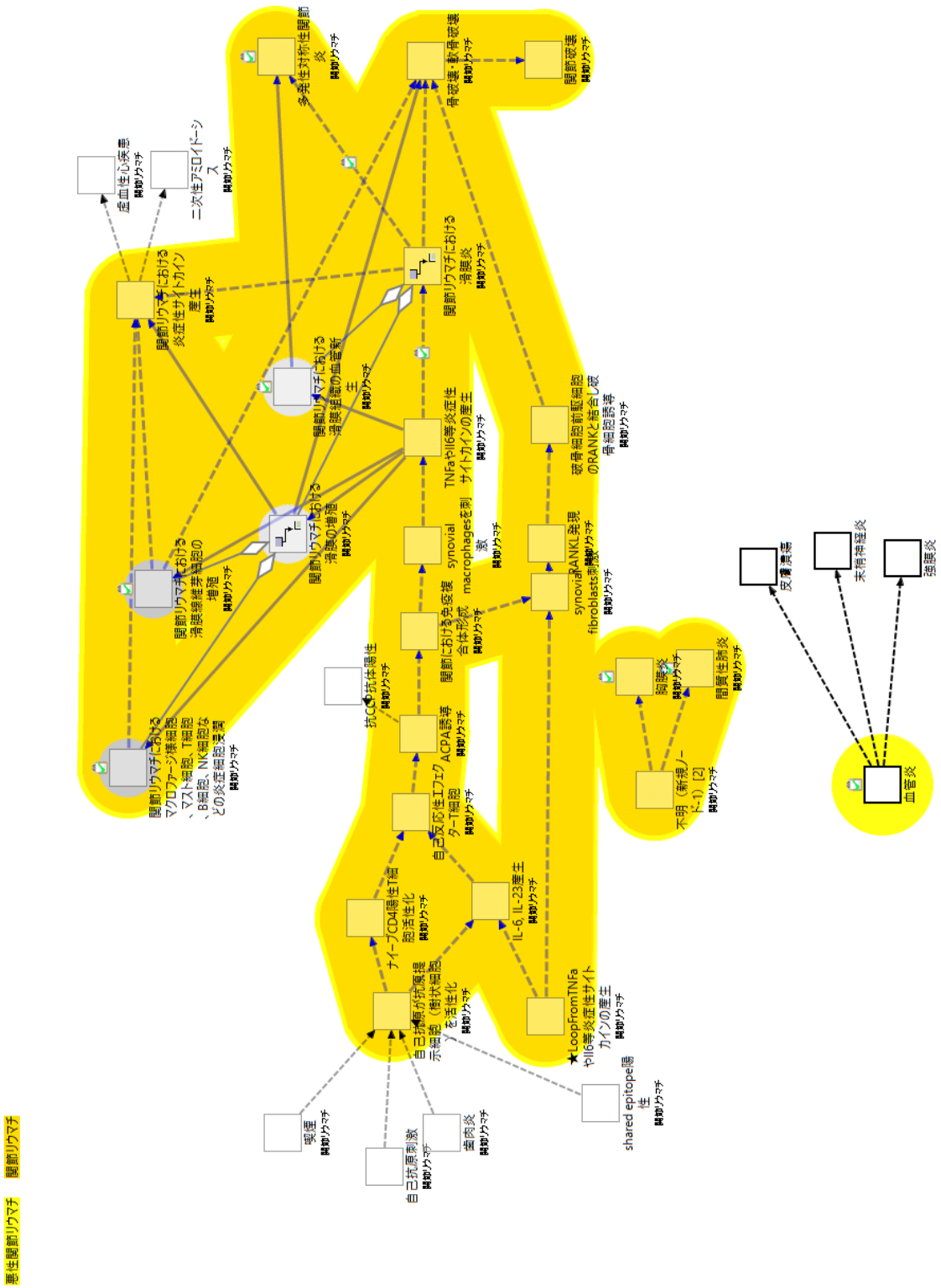

Figure 7. アレルギーリウマチ内科:悪性関節リウマチ

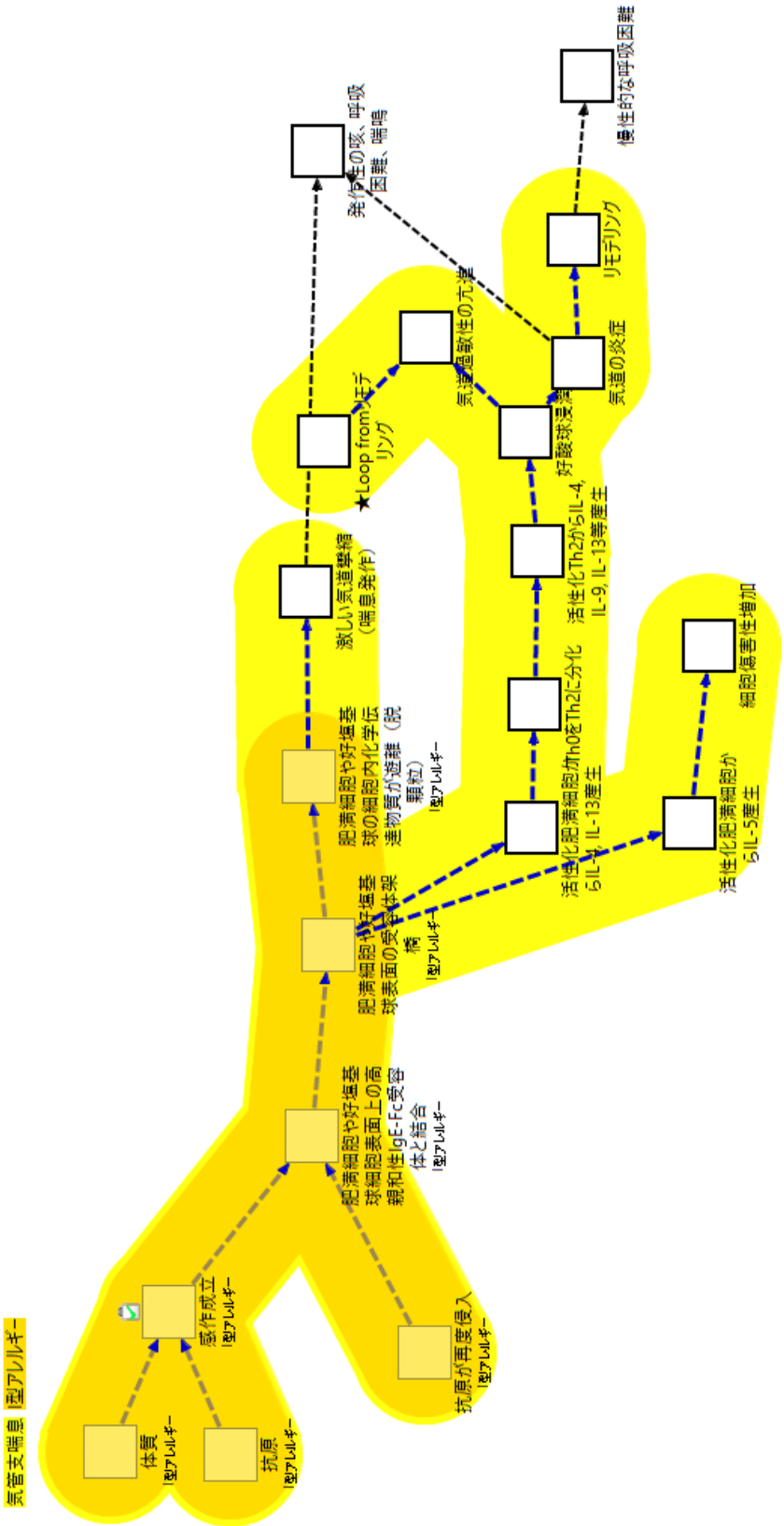

Figure 8. アレルギーリウマチ内科:気管支喘息

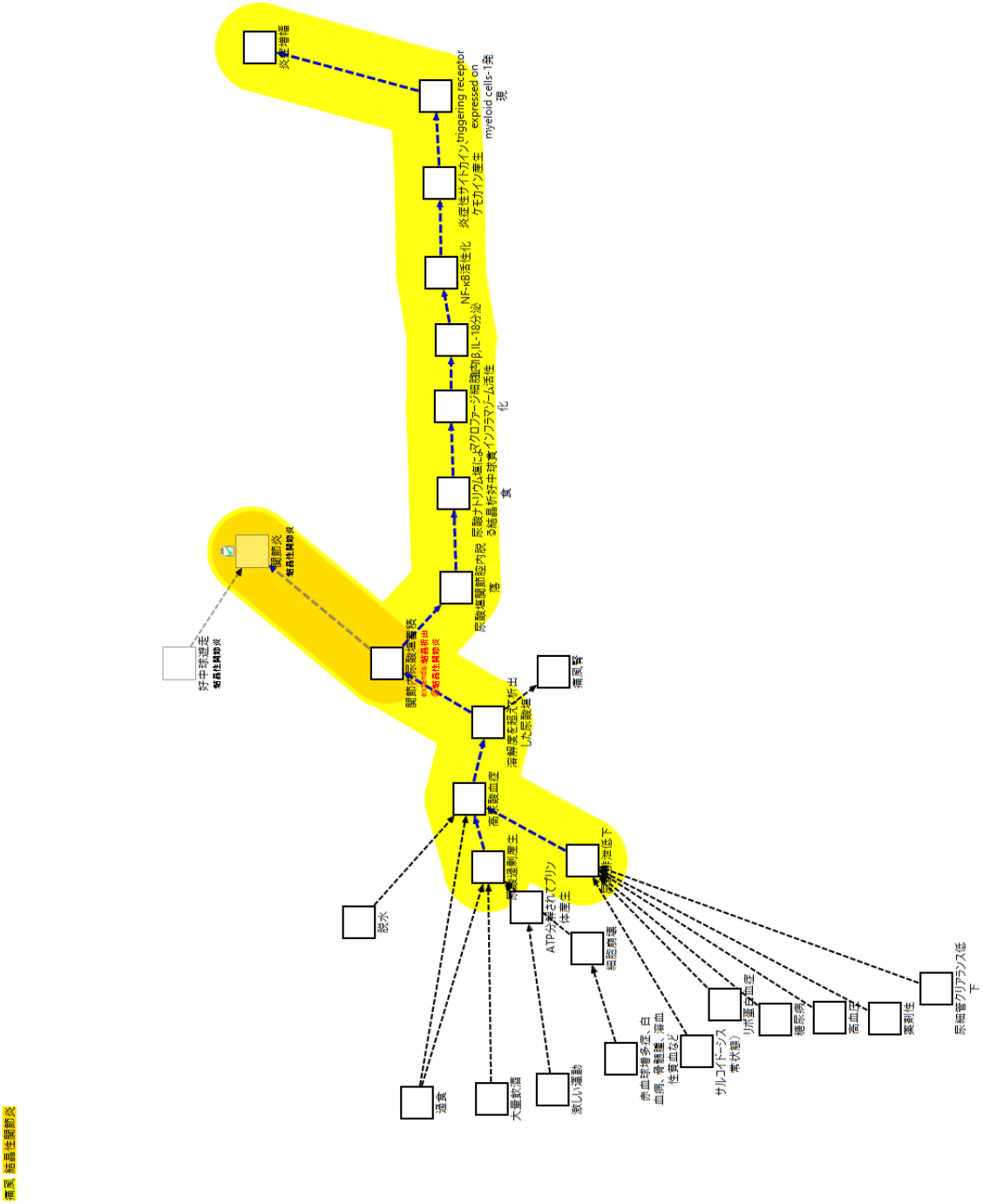

Figure 9. アレルギーリウマチ内科:痛風

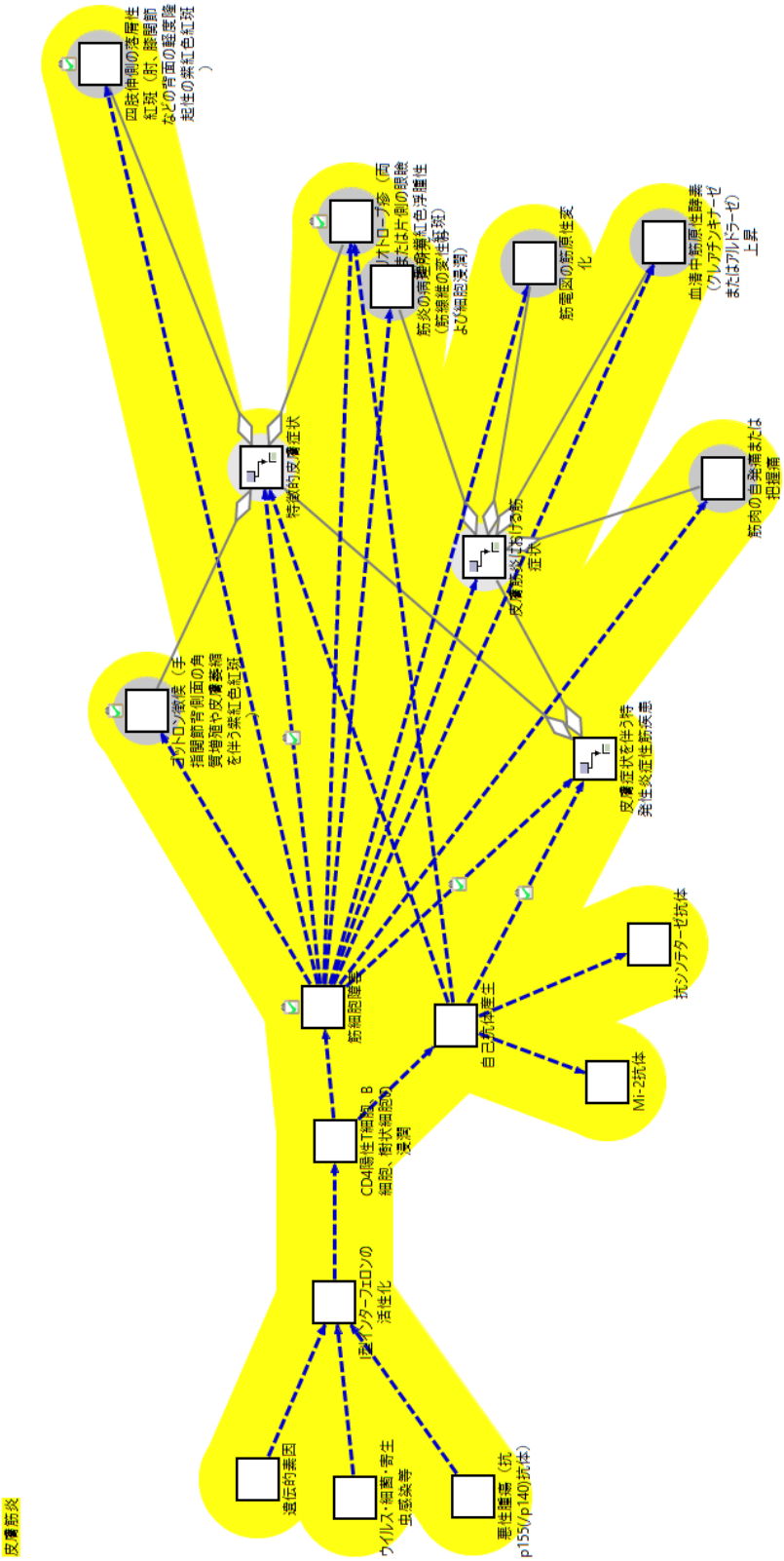

Figure 10. アレルギーリウマチ内科:皮膚筋炎

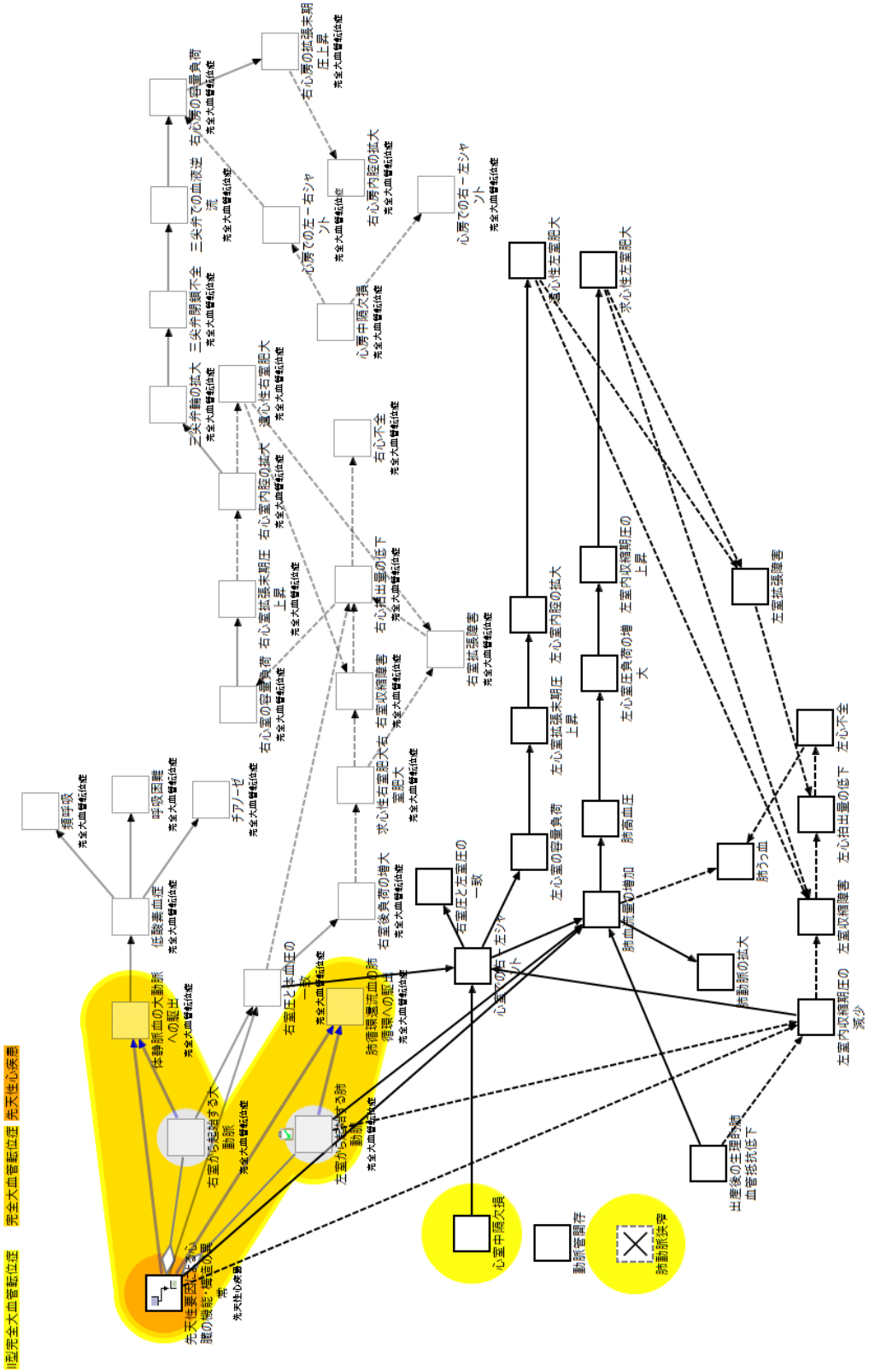

Figure 11. 循環器内科:II 型完全大血管転位症

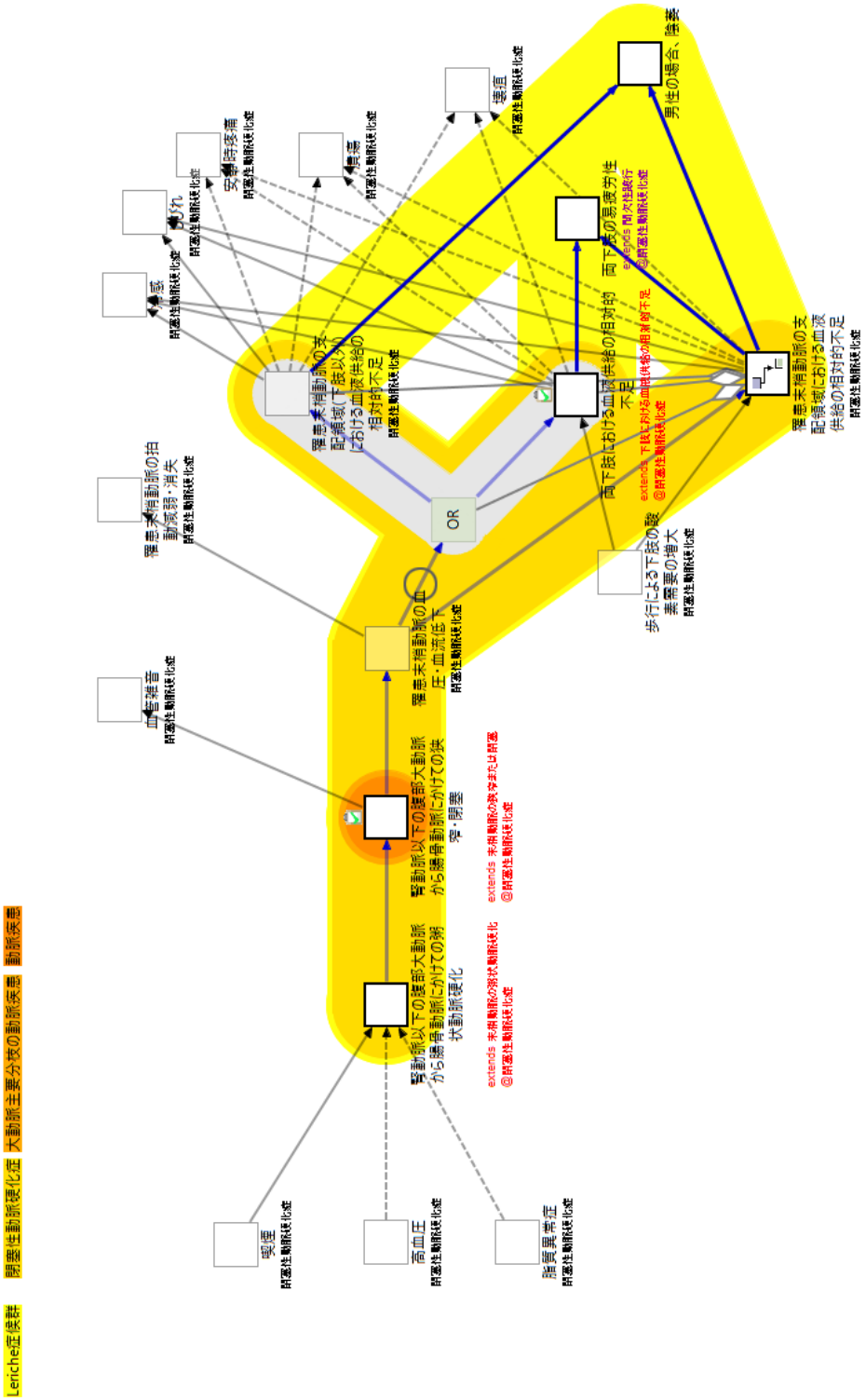

Figure 12. 循環器内科:Leriche 症候群

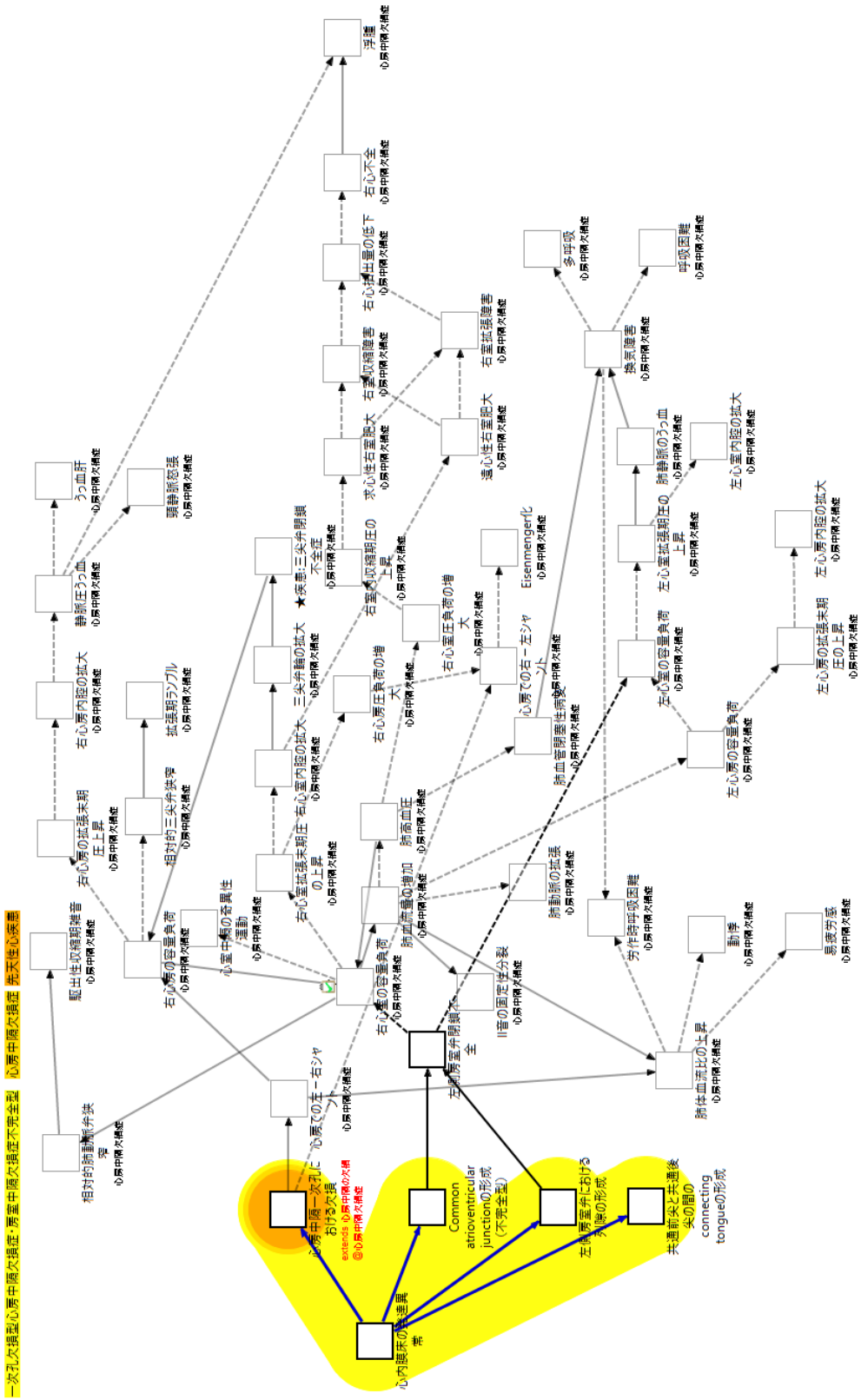

Figure 13. 循環器内科:一次孔欠損型心房中隔欠損症・房室中隔欠損症不完全型

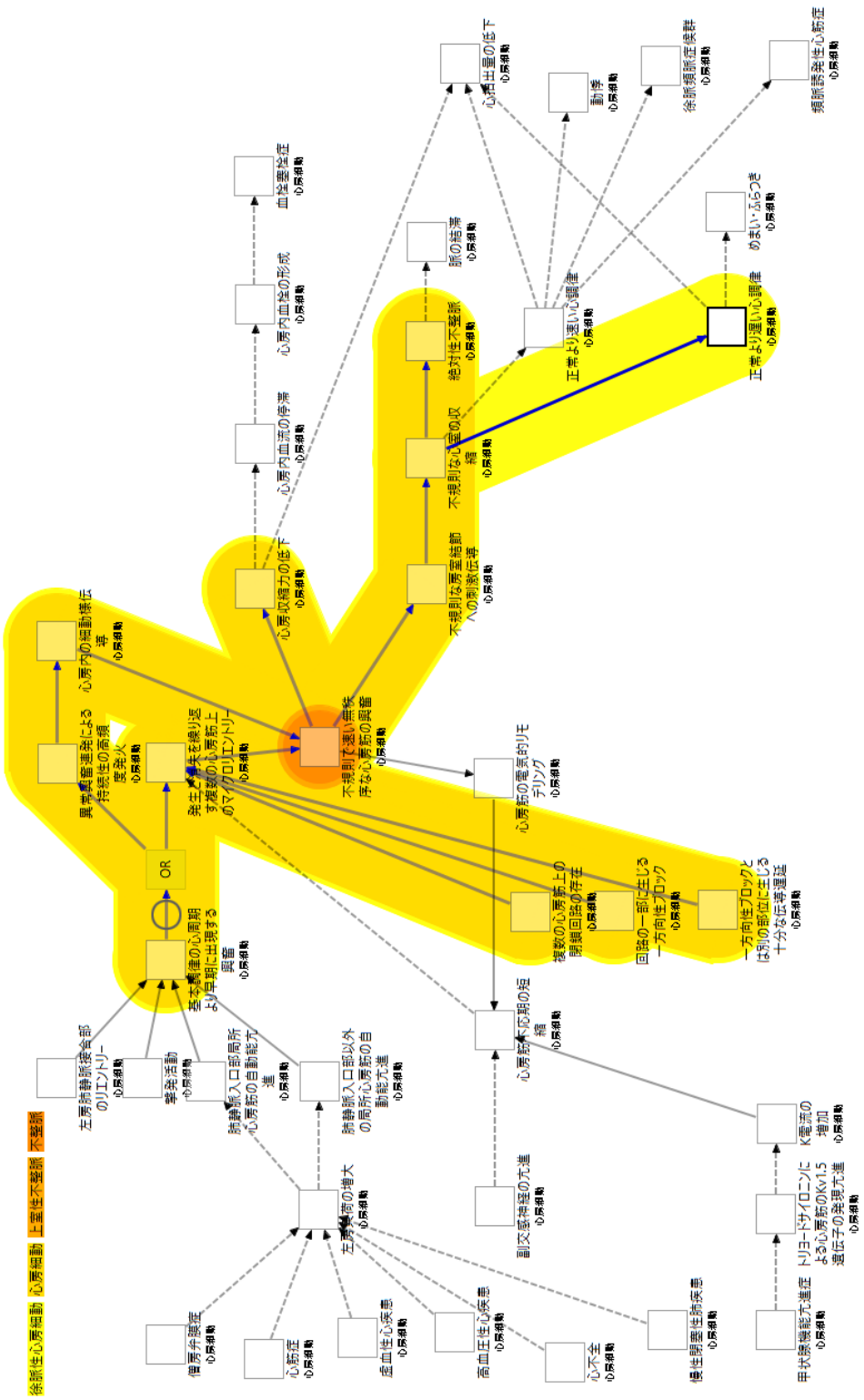

Figure 14. 循環器内科:徐脈性心房細動

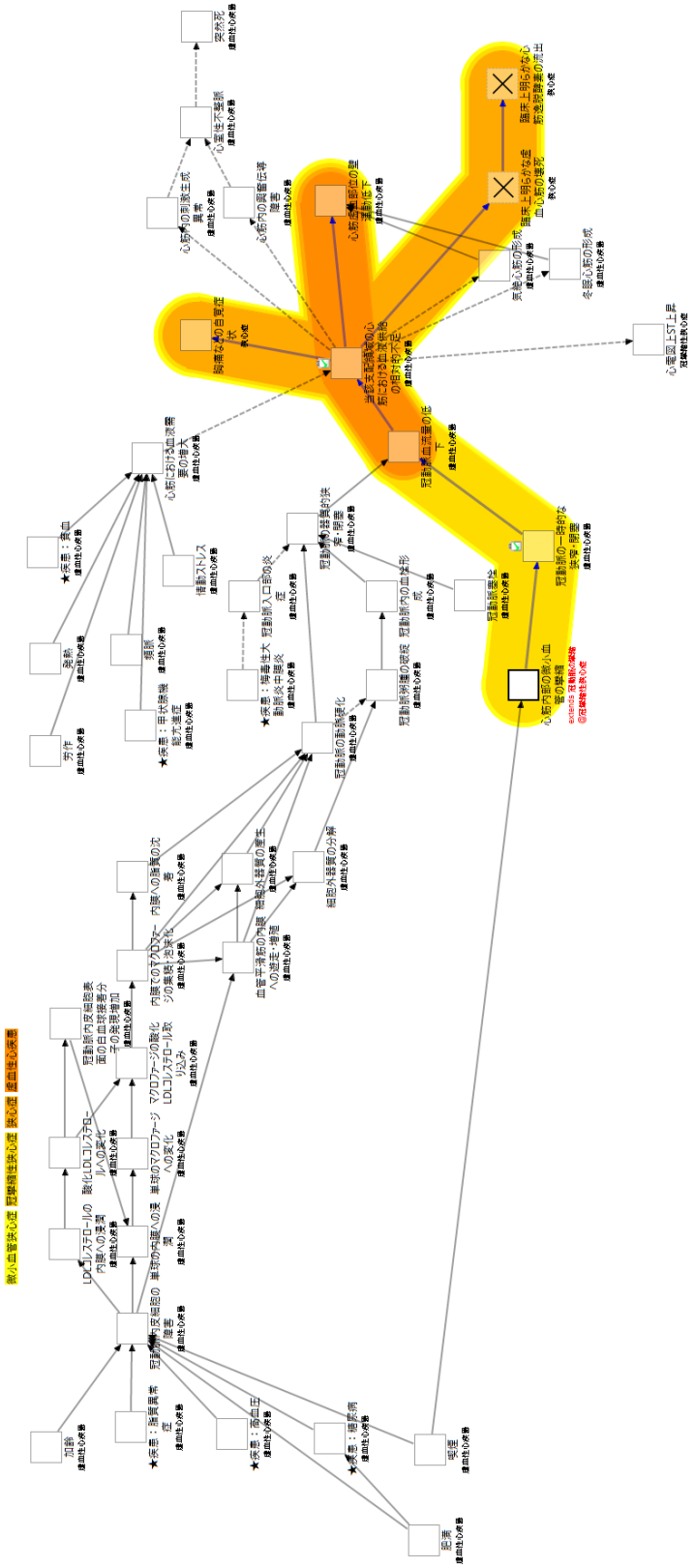

Figure 15. 循環器内科:微小血管狭心症

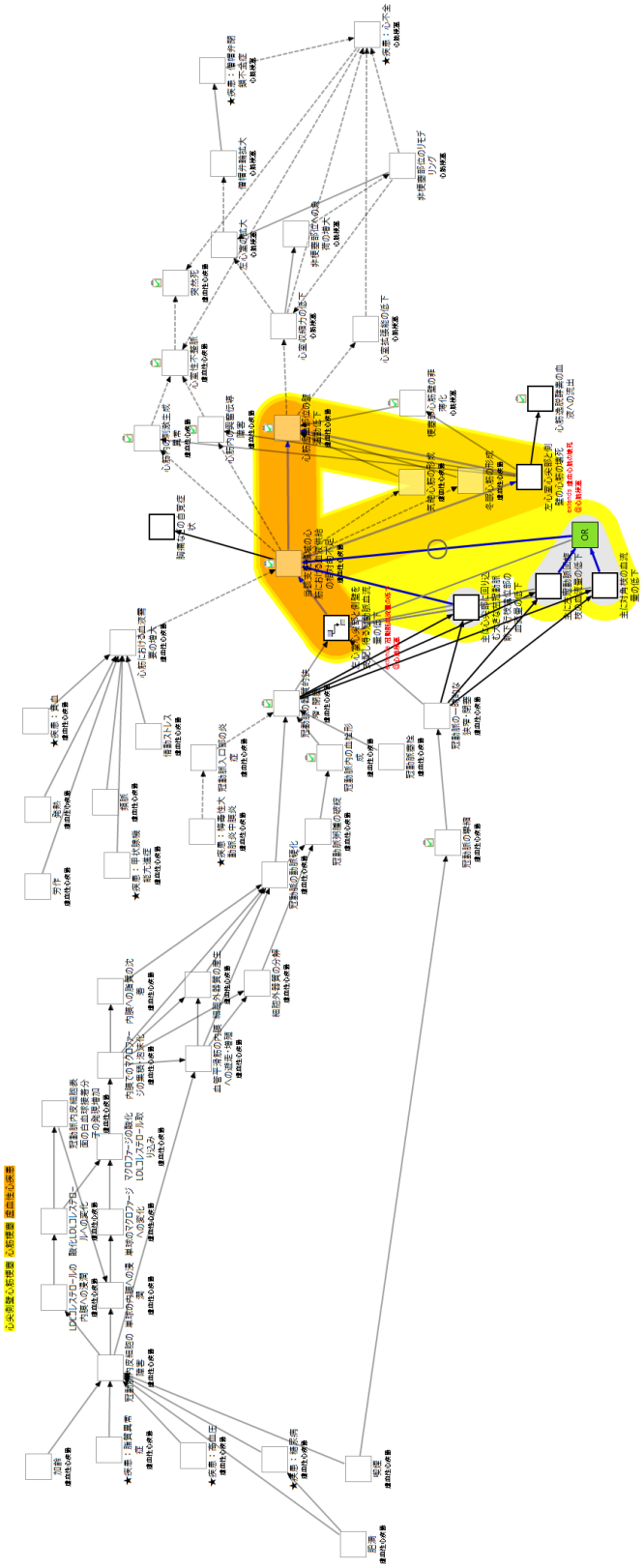

Figure 16. 循環器内科:心尖側壁心筋梗塞

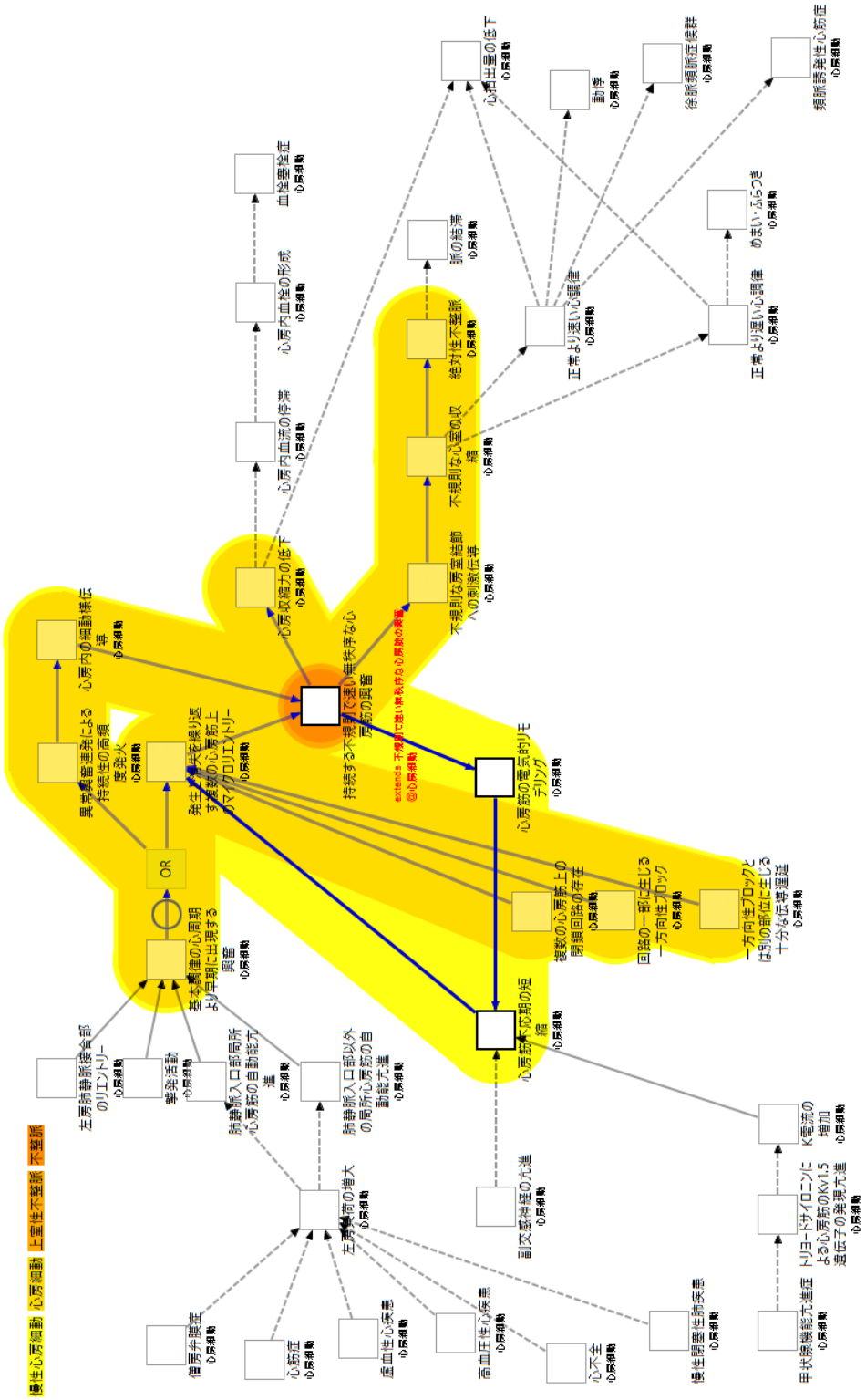

Figure 17. 循環器内科:慢性心房細動

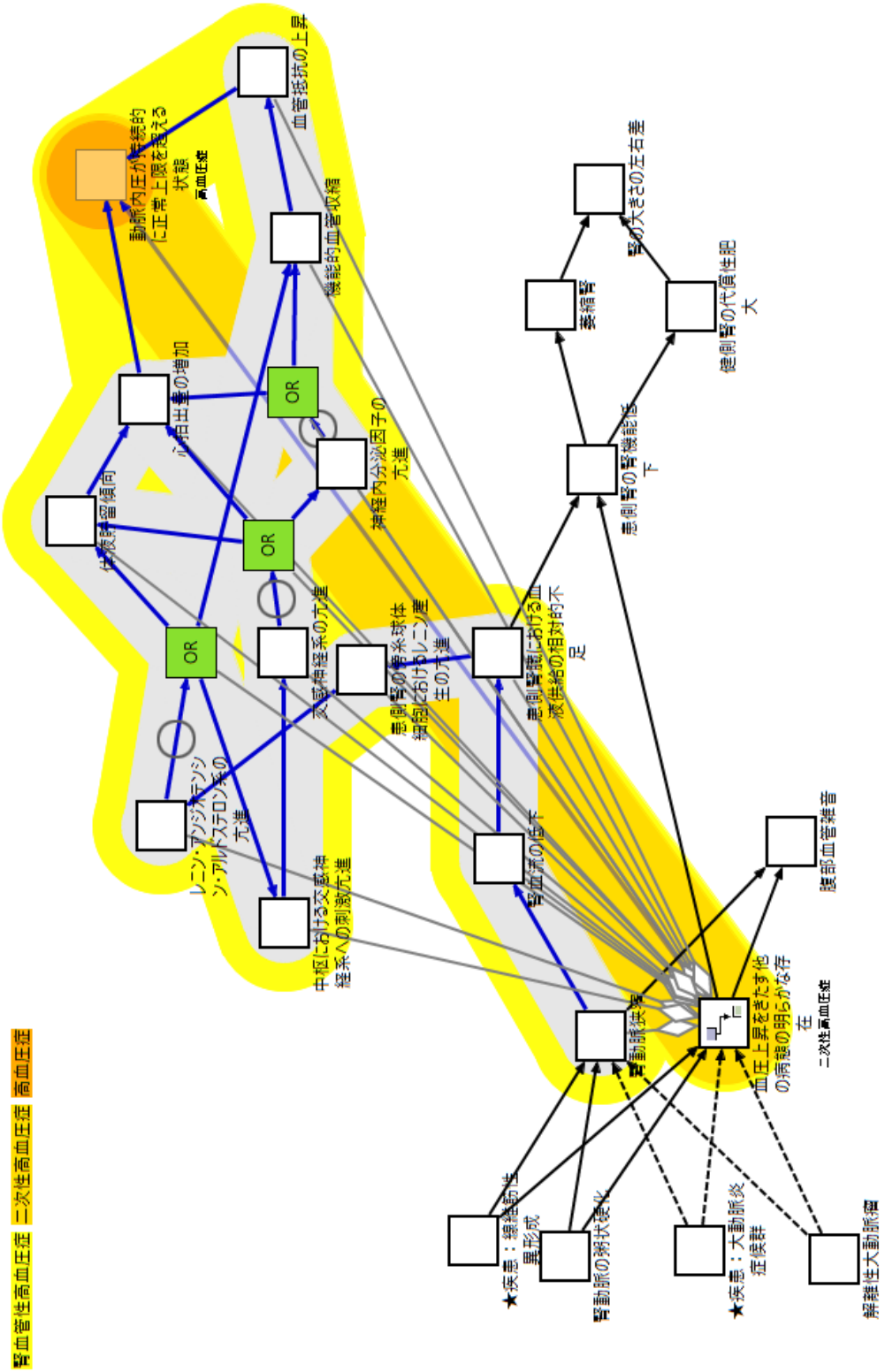

Figure 18. 循環器内科:腎血管性高血圧症

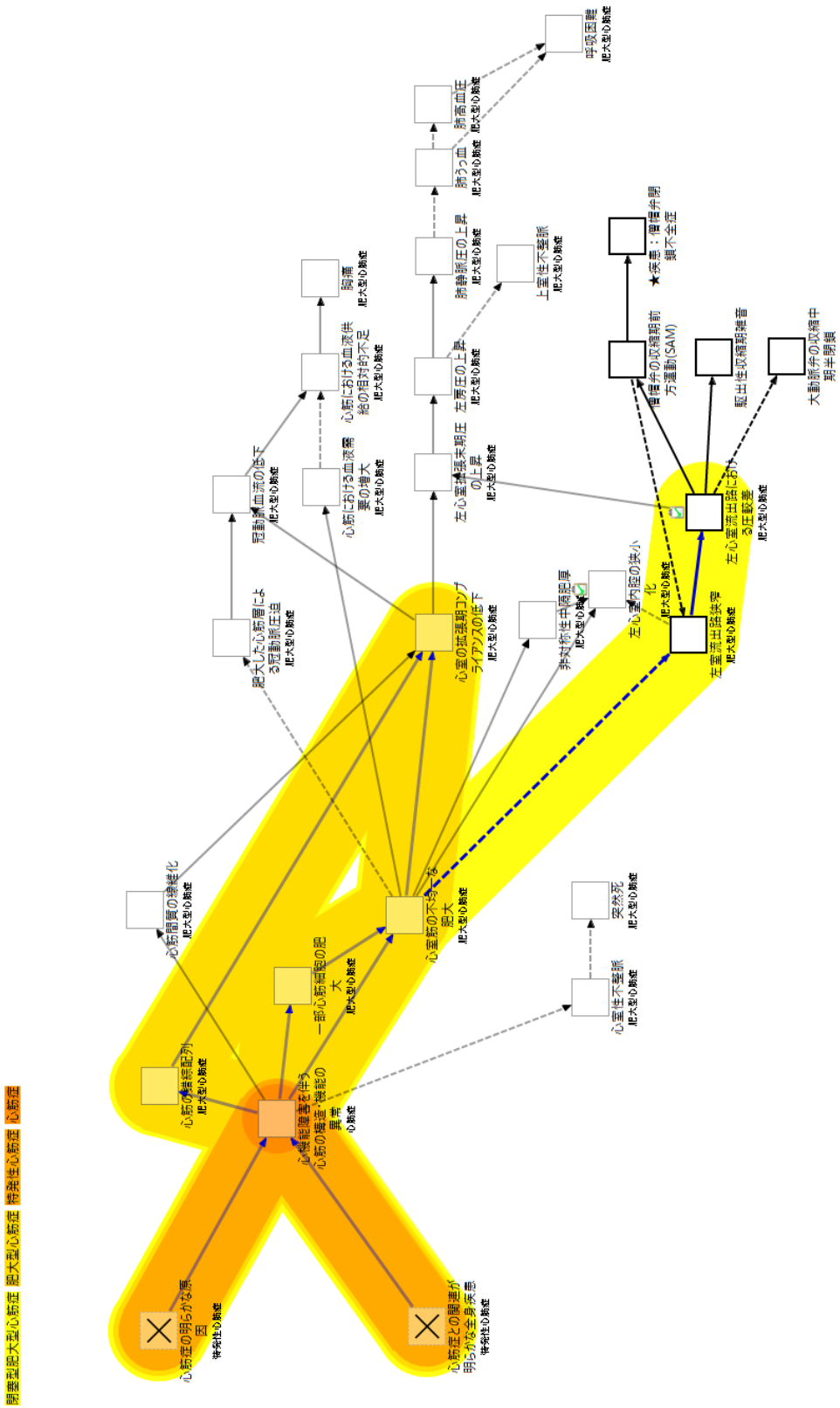

Figure 19. 循環器内科:閉塞型肥大型心筋症

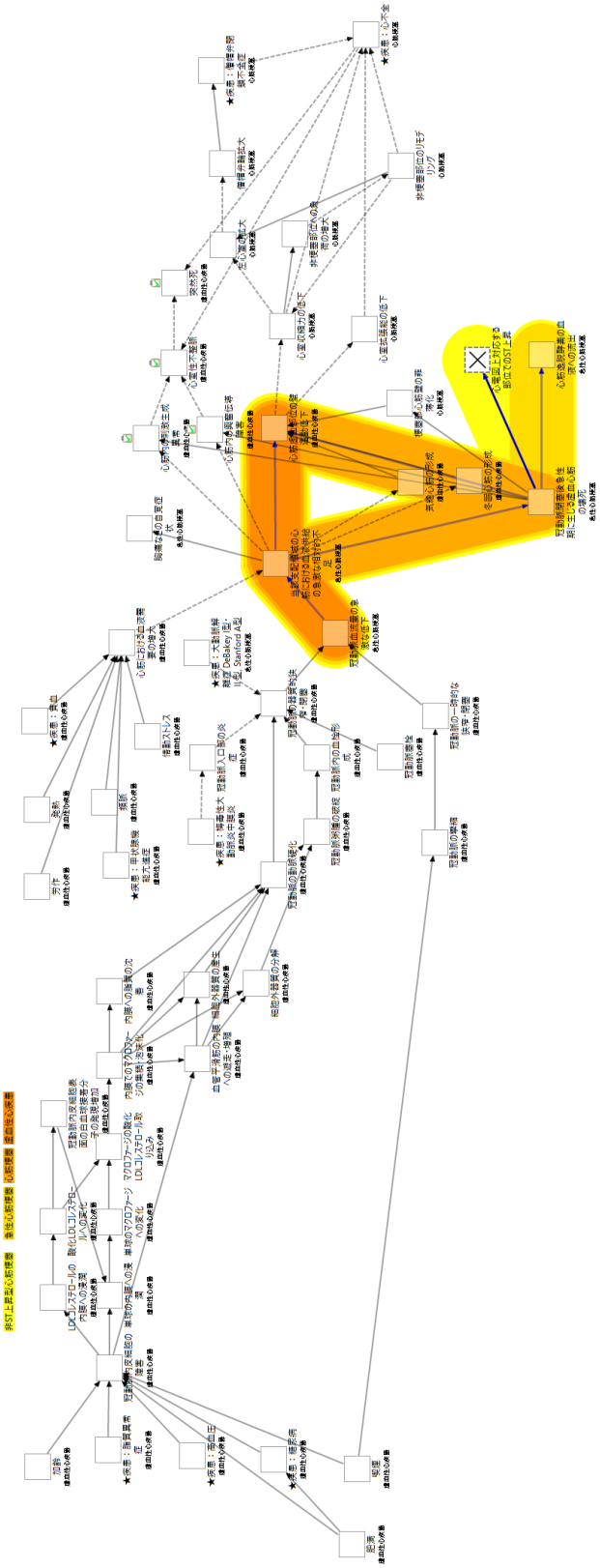

Figure 20. 循環器内科:非 ST 上昇型心筋梗塞

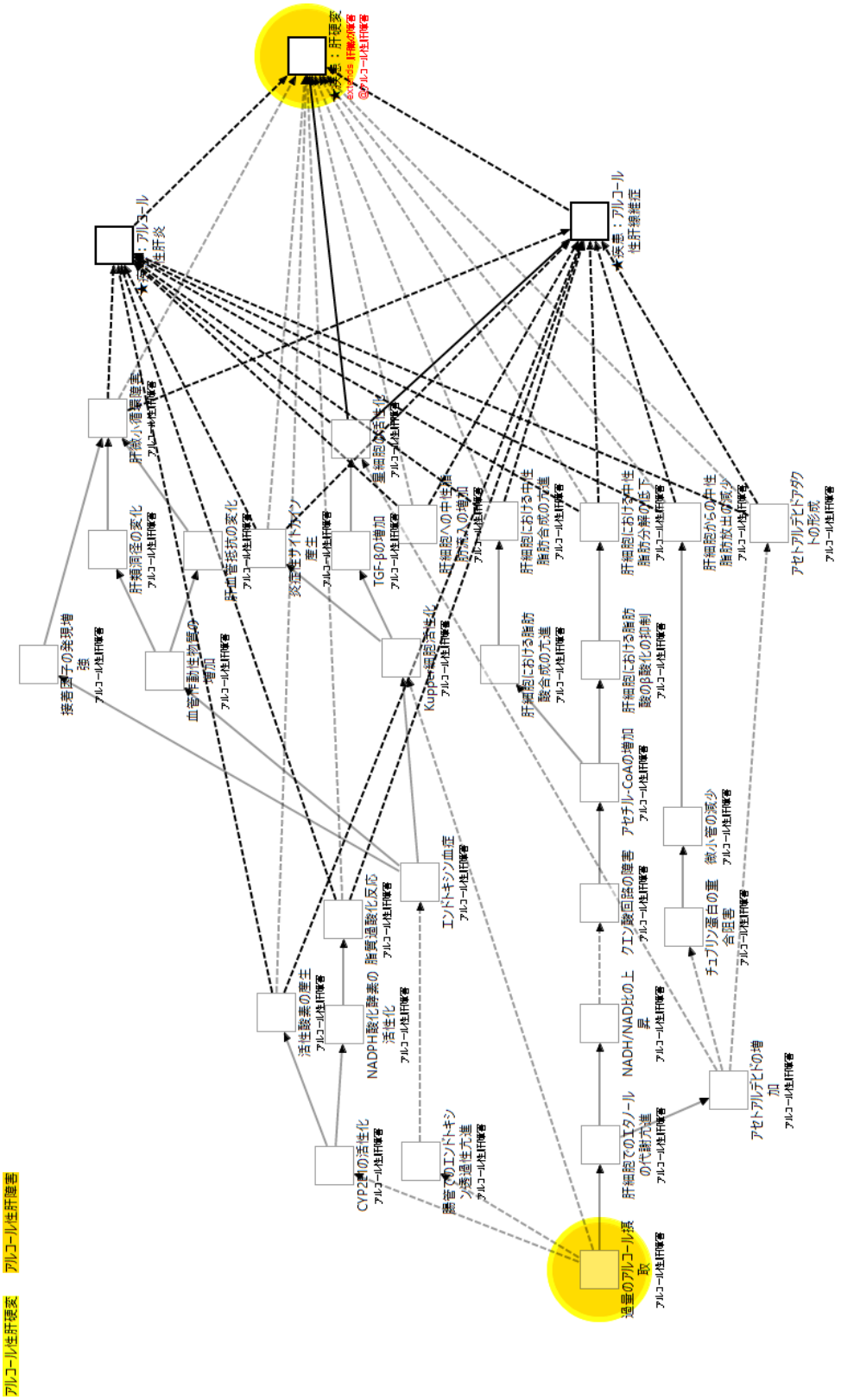

Figure 21. 消化器内科:アルコール性肝硬変

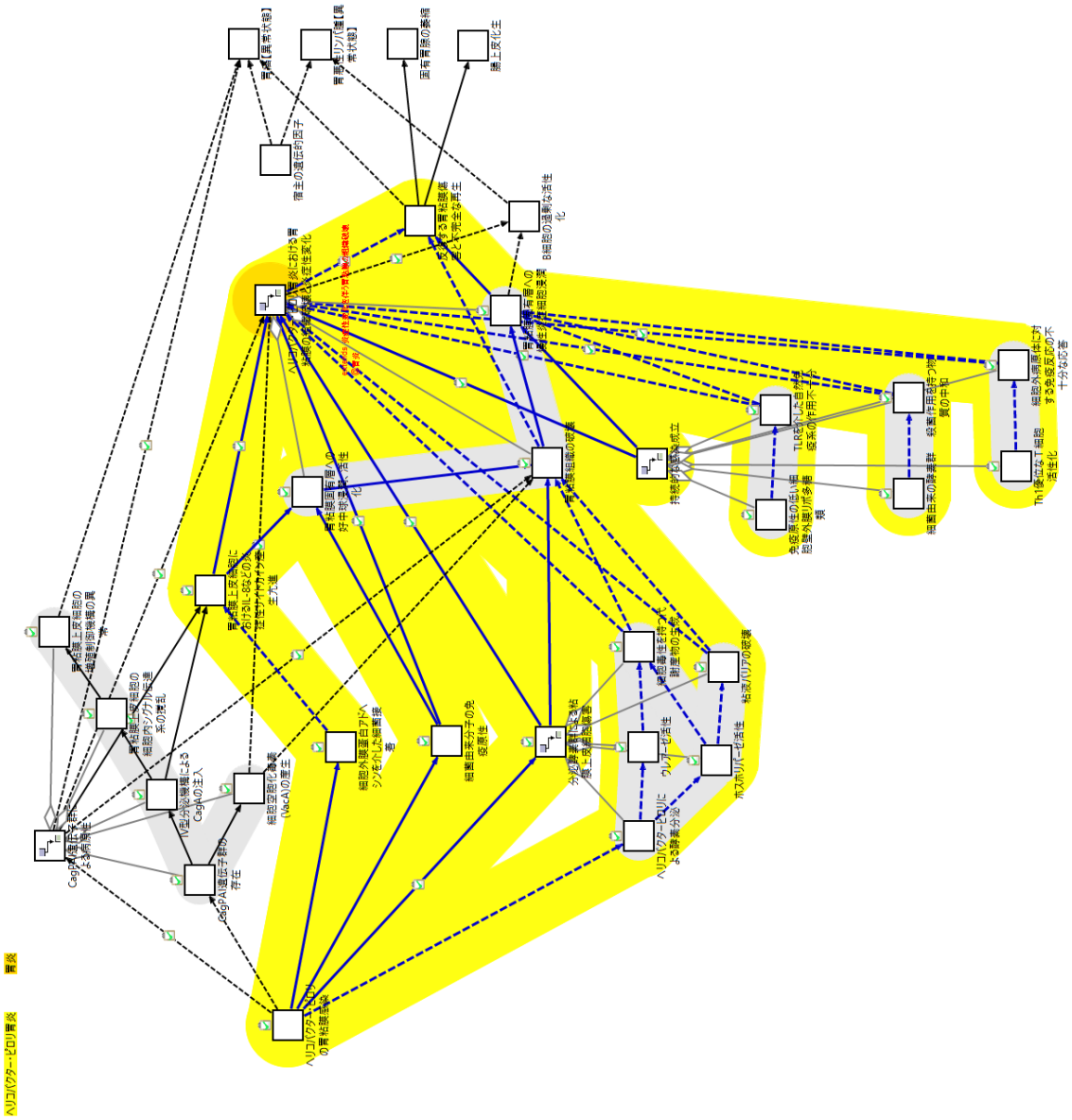

Figure 22. 消化器内科:ヘリコバクター・ピロリ胃炎

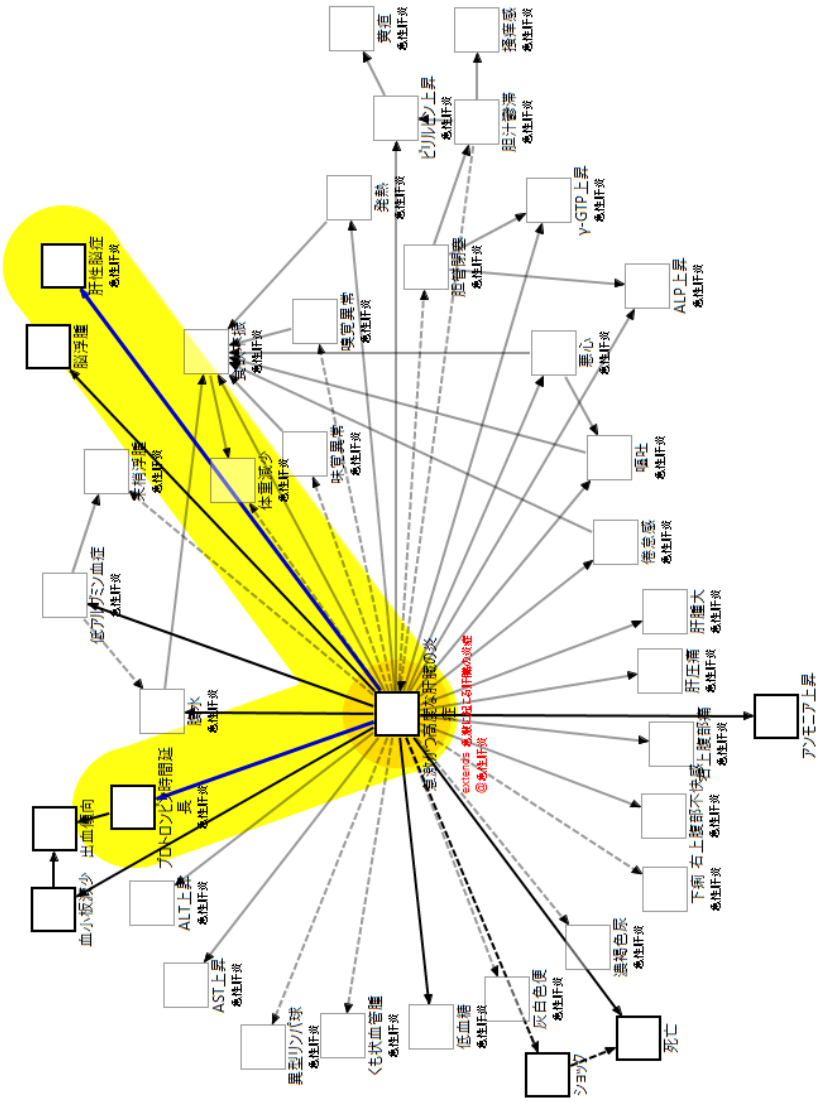

Figure 23. 消化器内科:劇症肝炎

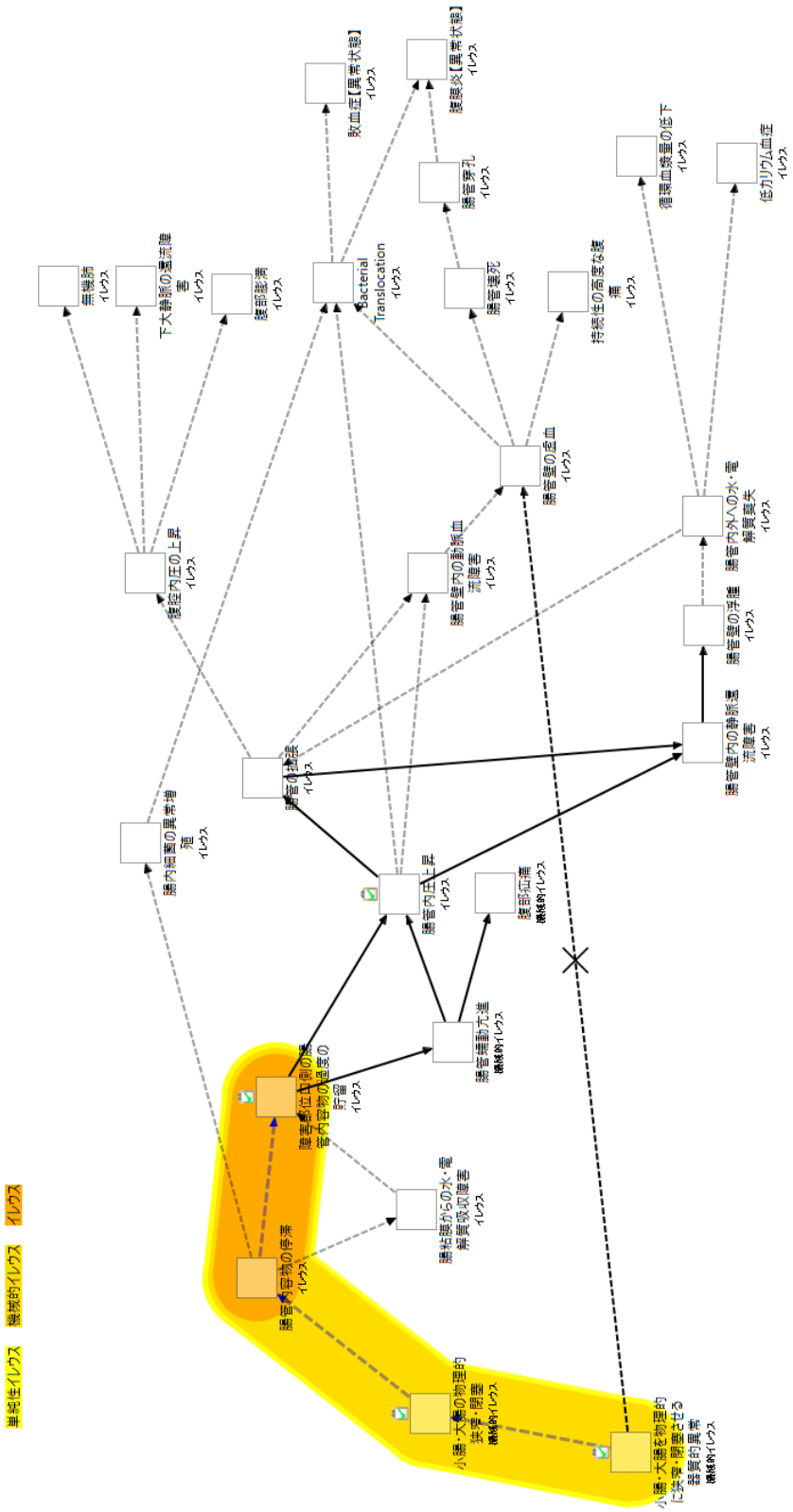

Figure 24. 消化器内科:単純性イレウス

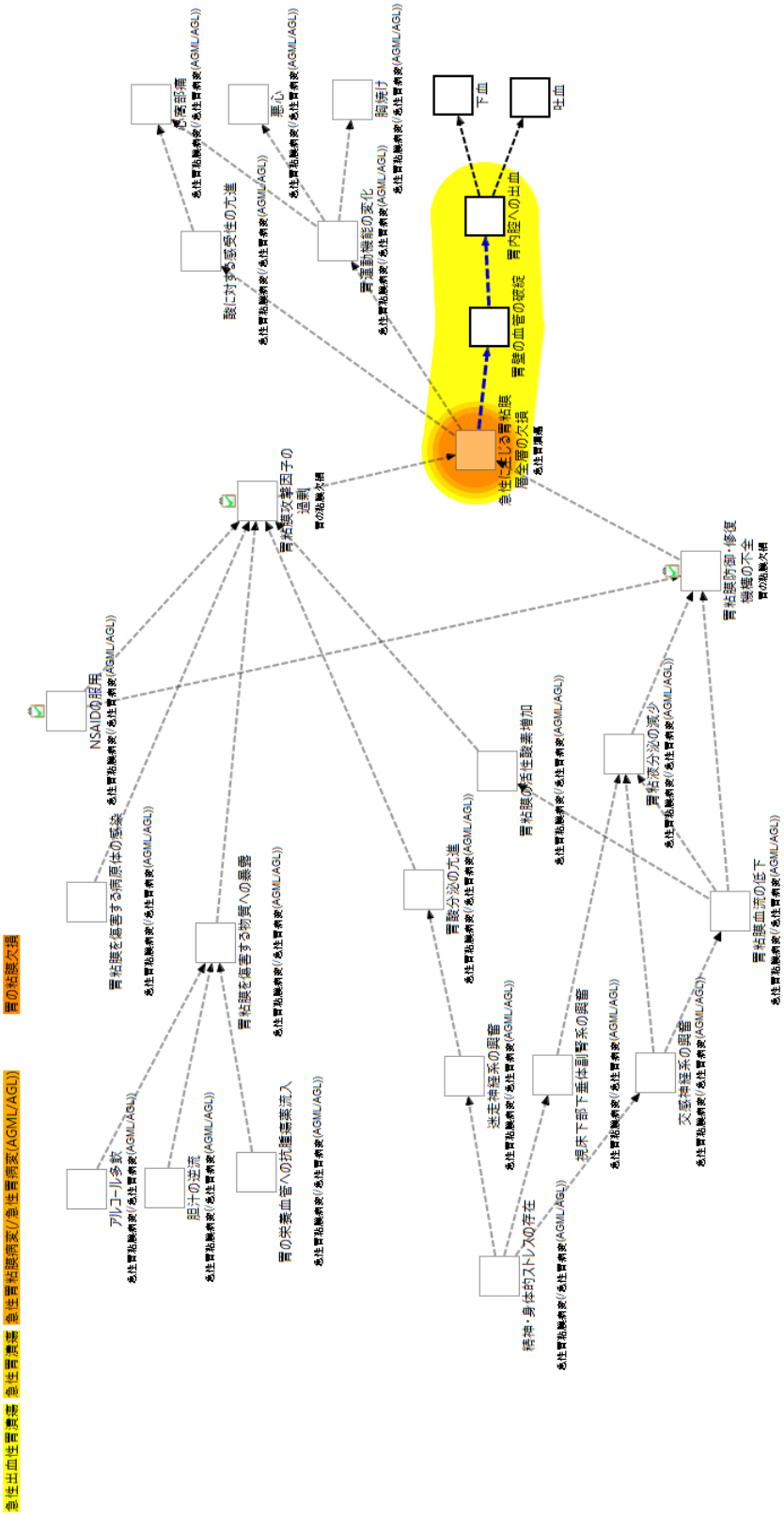

Figure 25. 消化器内科:急性出血性胃潰瘍

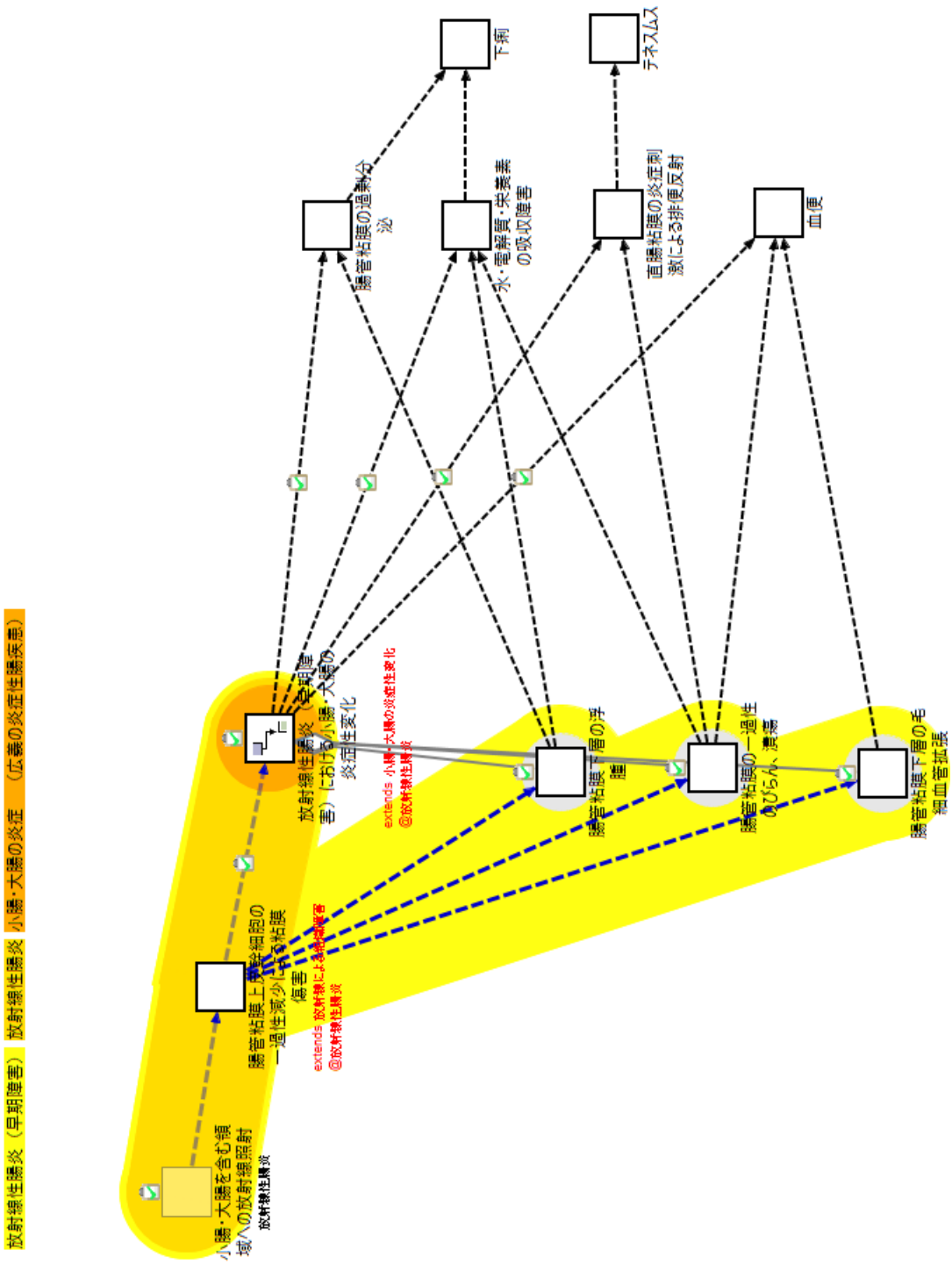

Figure 26. 消化器内科:放射線性腸炎（早期障害）

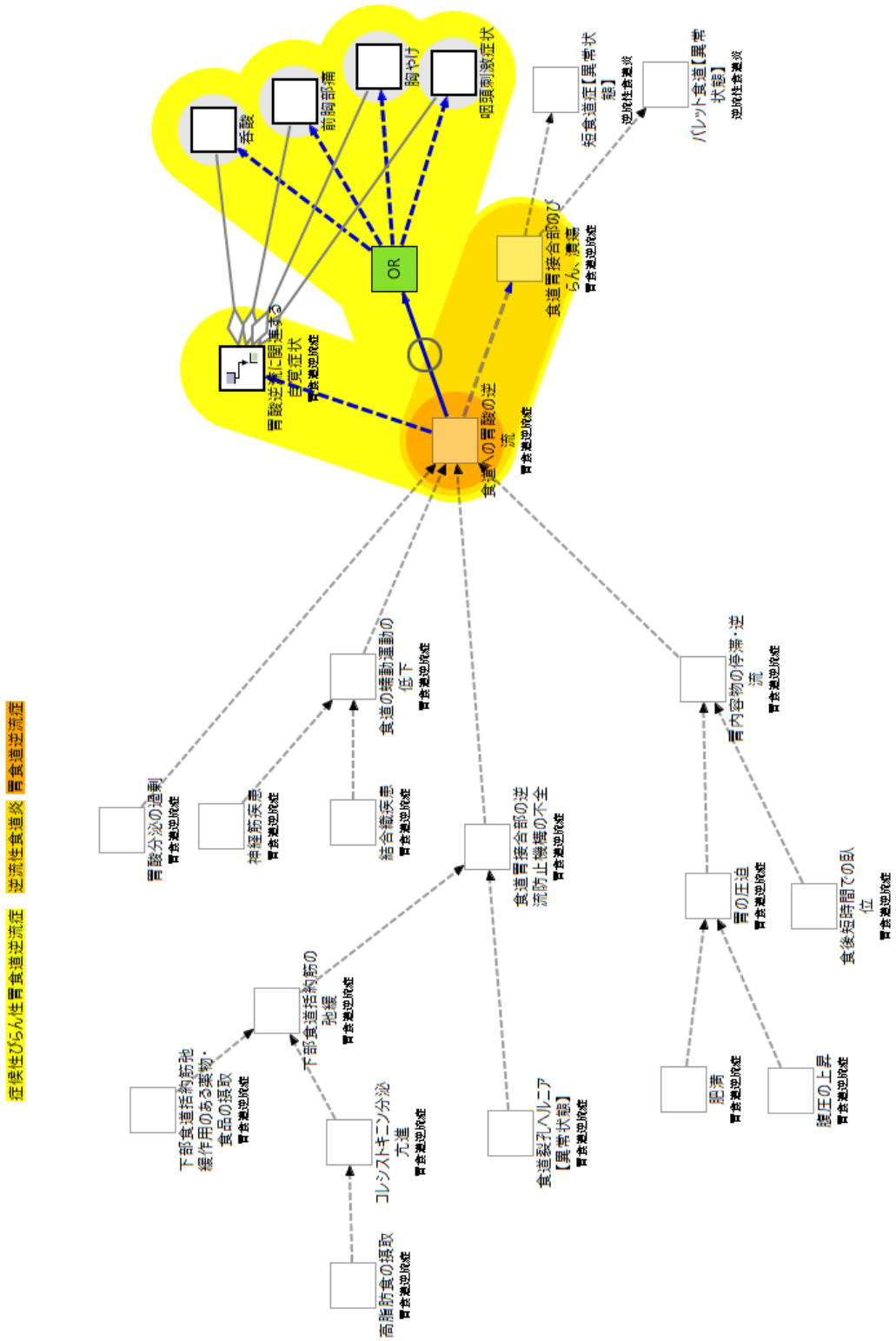

Figure 27. 消化器内科:症候性びらん性胃食道逆流症

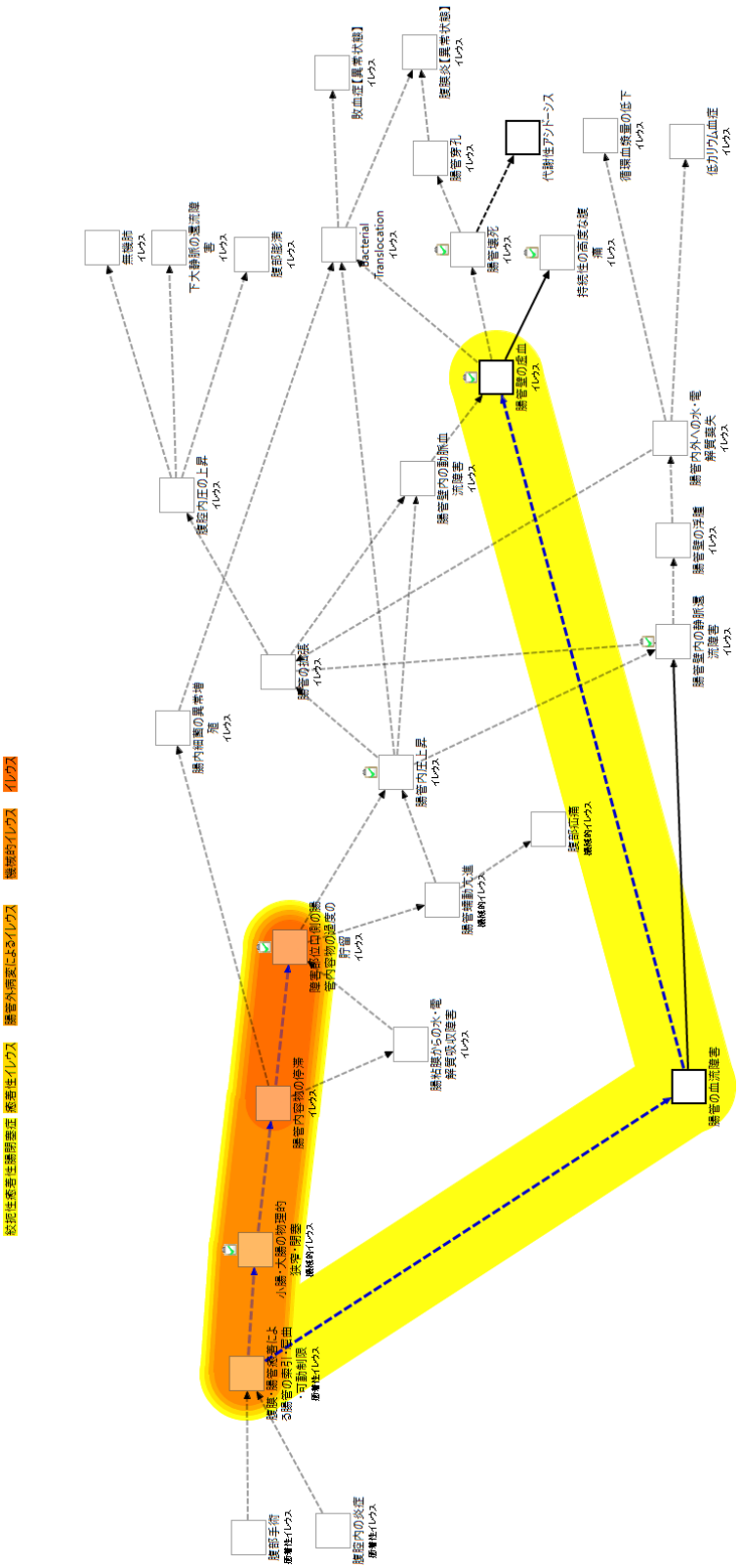

Figure 28. 消化器内科:絞扼性癒着性腸閉塞症

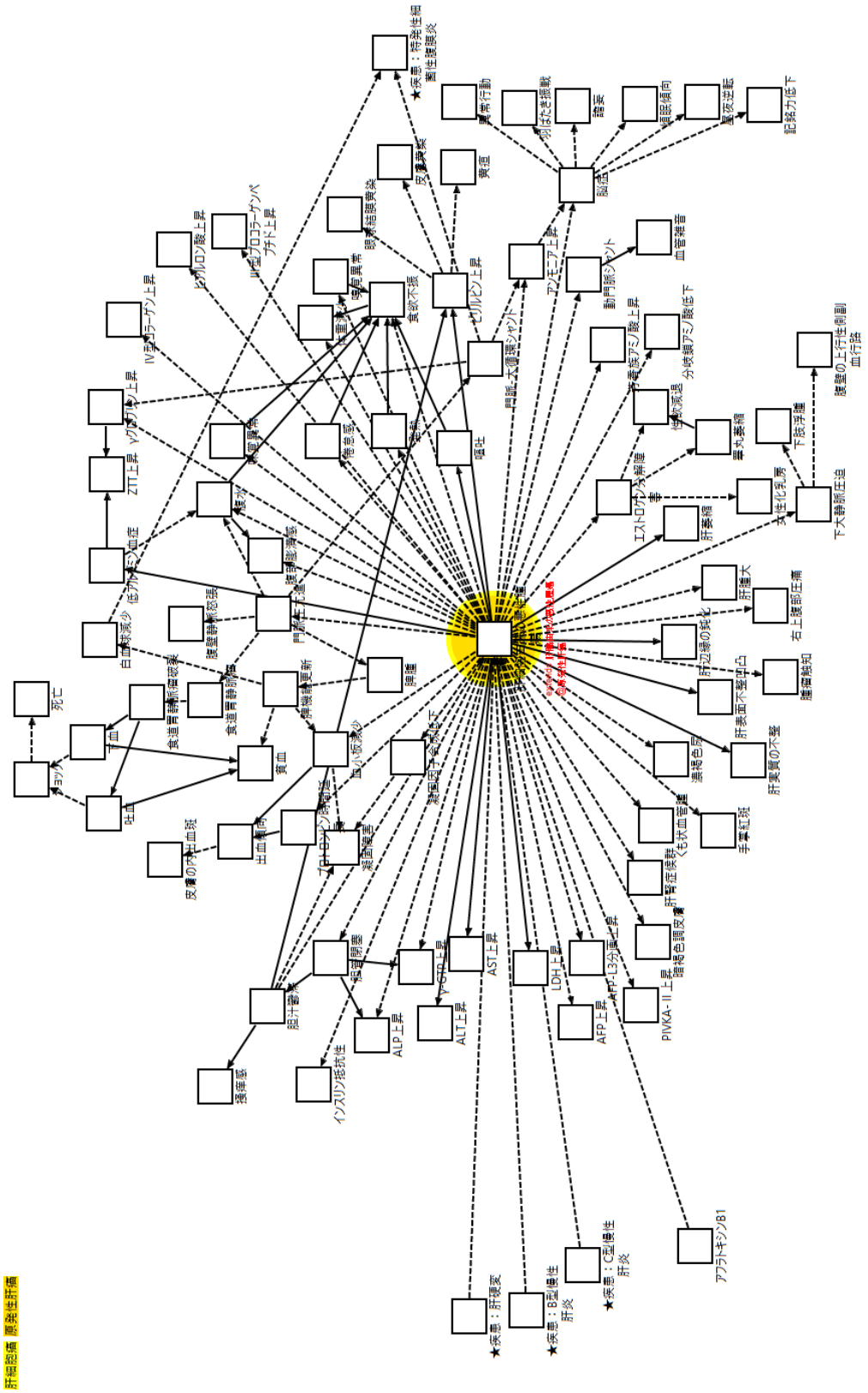

Figure 29. 消化器内科:肝細胞癌

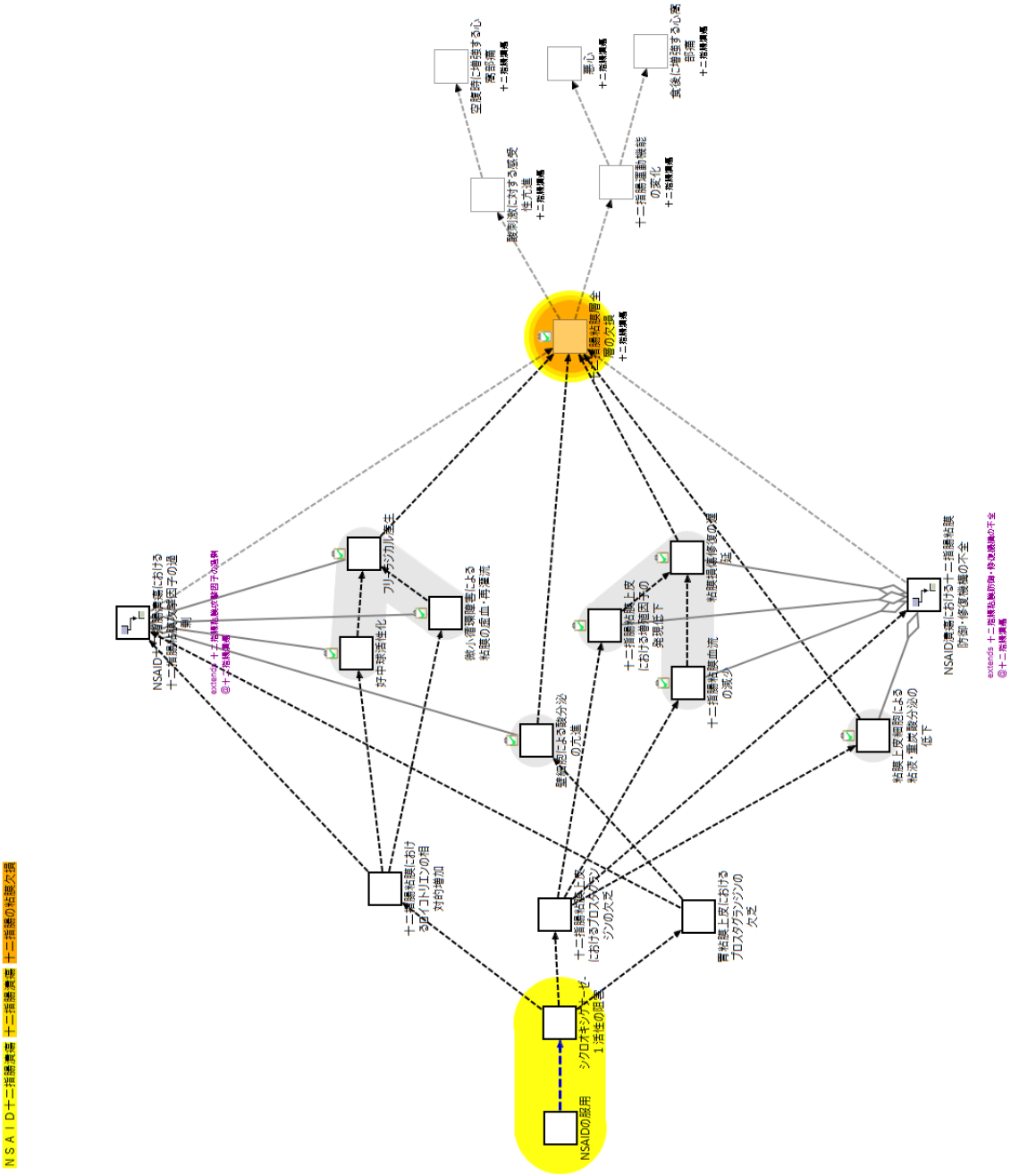

Figure 30. 消化器内科:ＮＳＡＩＤ十二指腸潰瘍

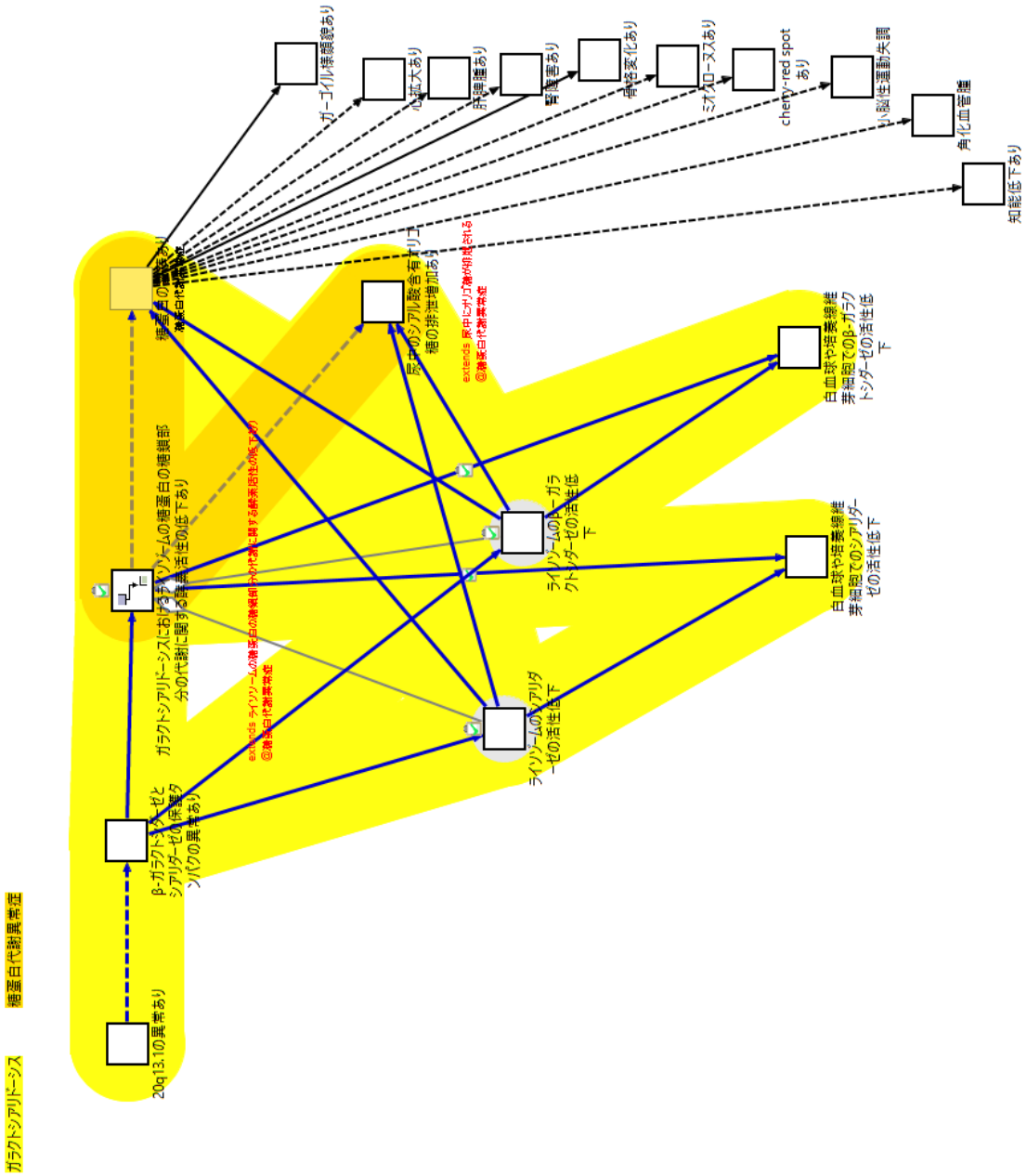

Figure 31. 神経内科:ガラクトシアリドーシス

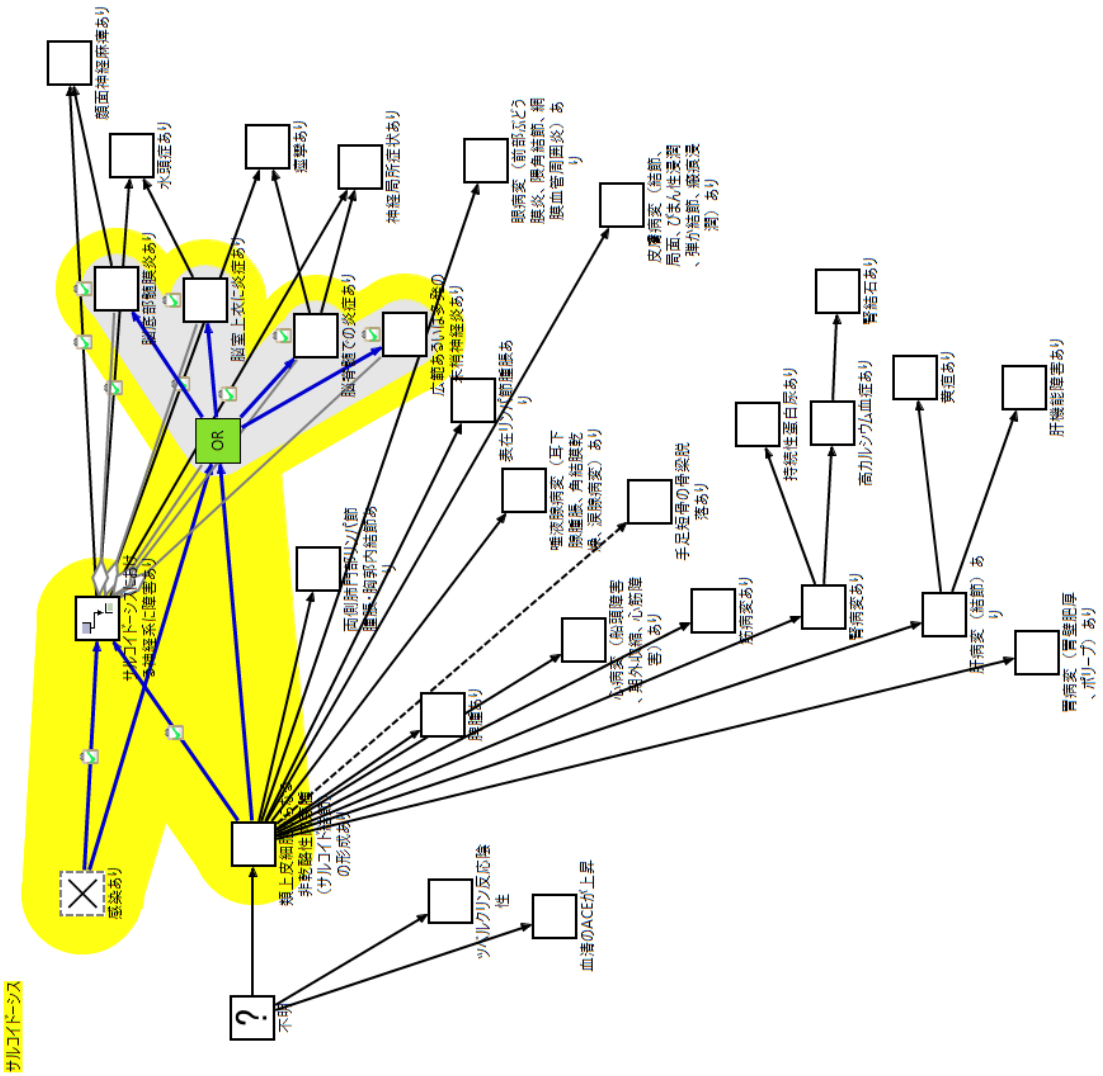

Figure 32. 神経内科:サルコイドーシス

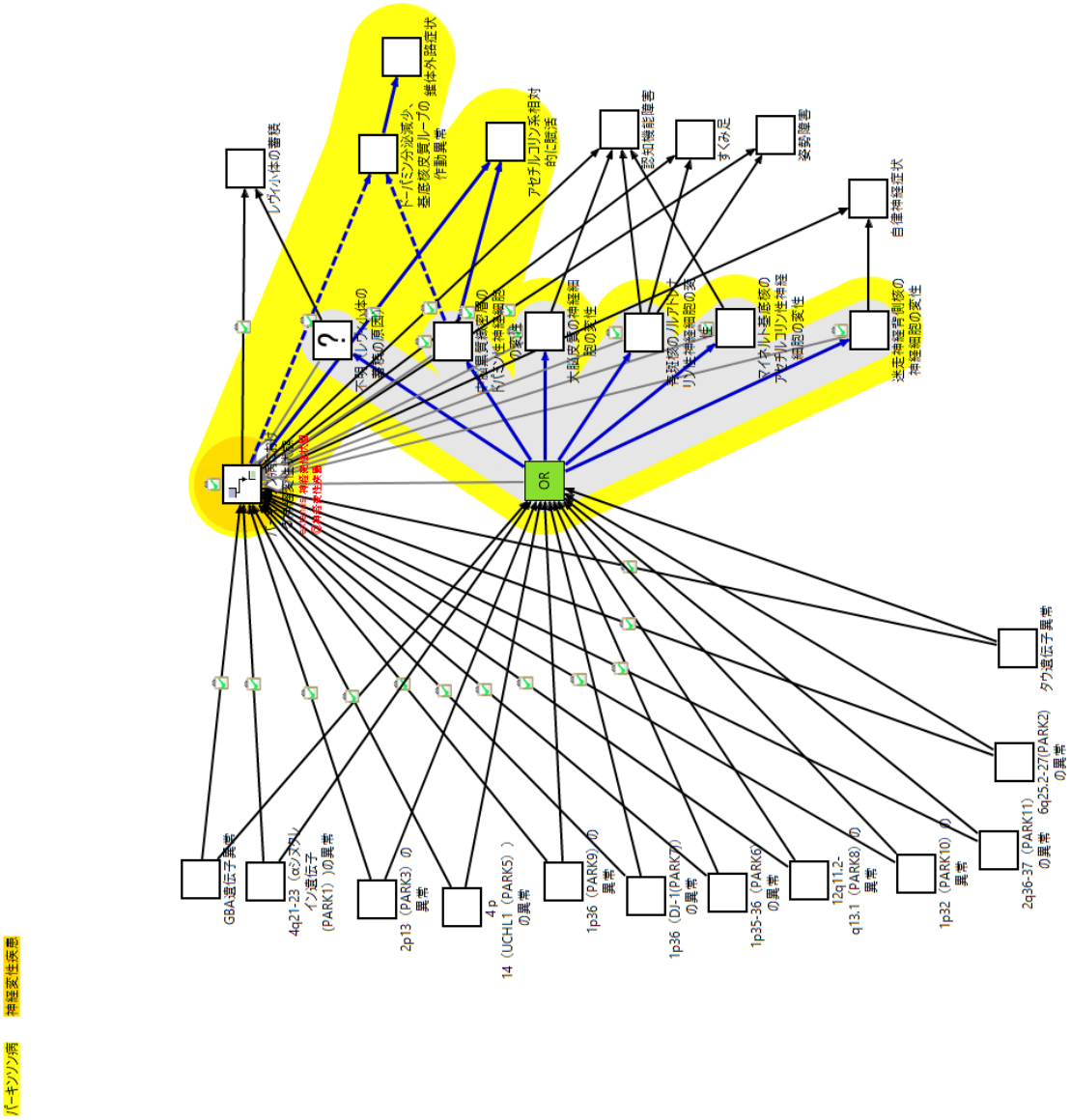

Figure 33. 神経内科:パーキンソン病

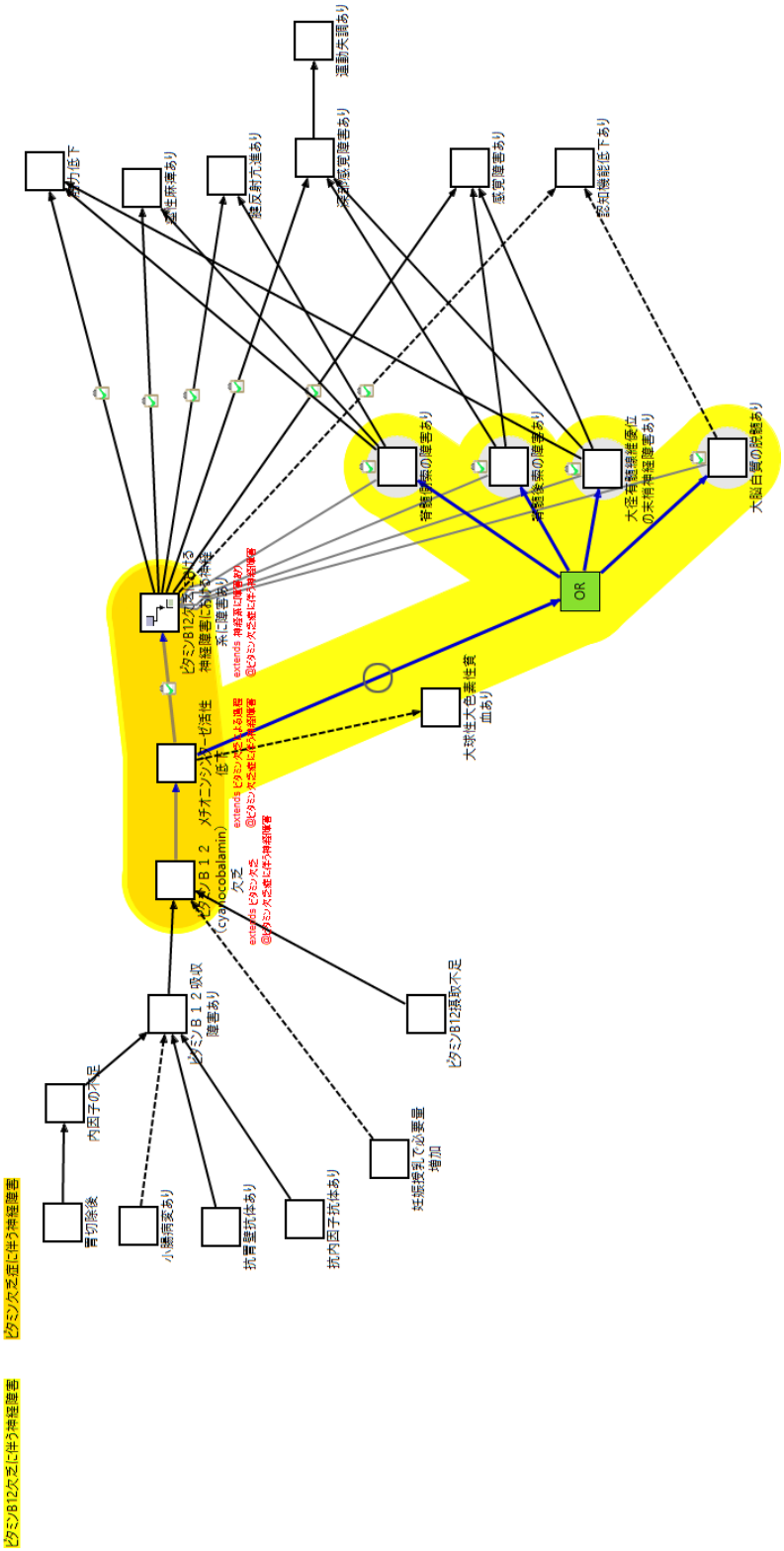

Figure 34. 神経内科:ビタミン B12 欠乏に伴う神経障害

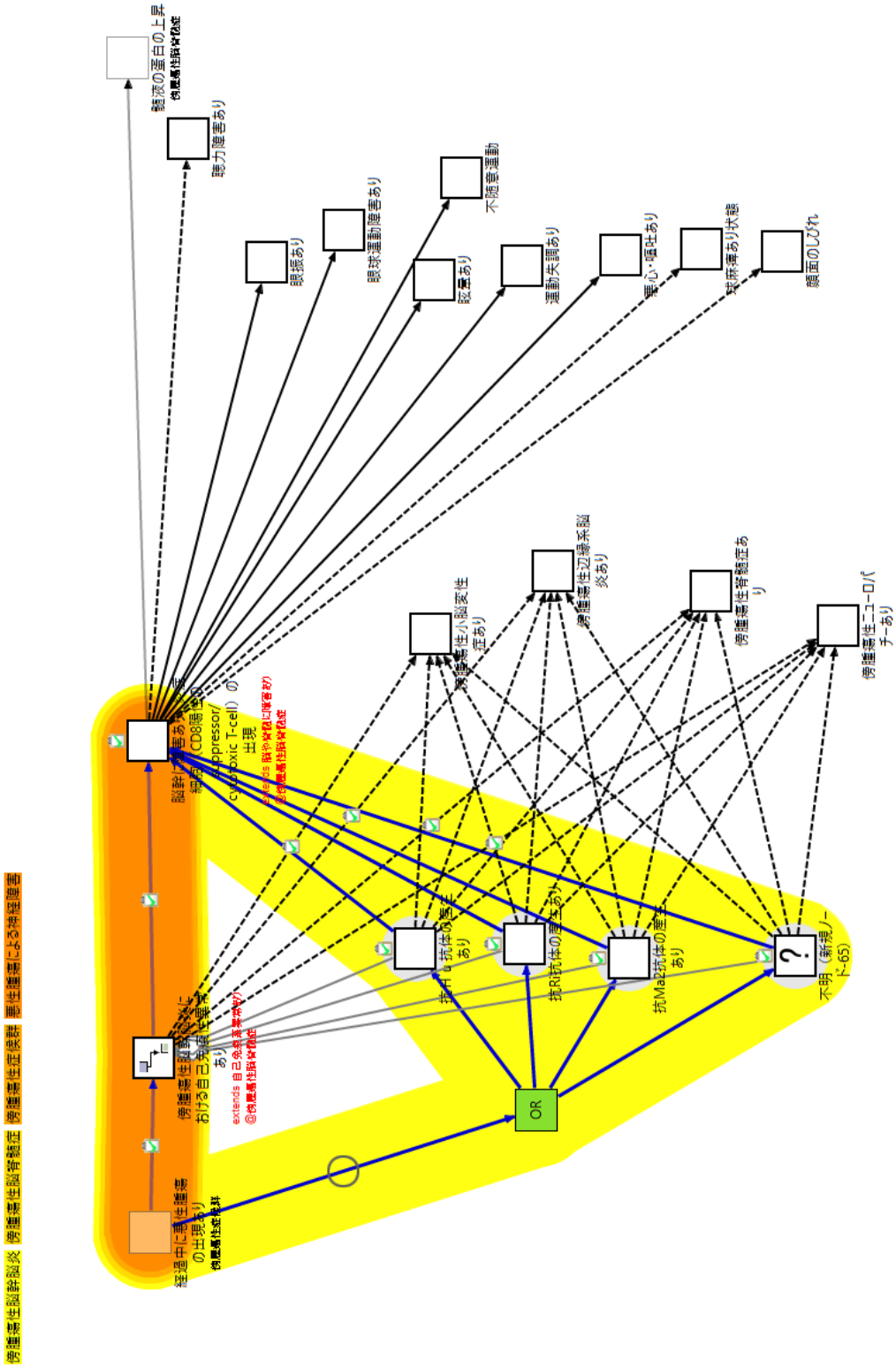

Figure 35. 神経内科:傍腫瘍性脳幹脳炎

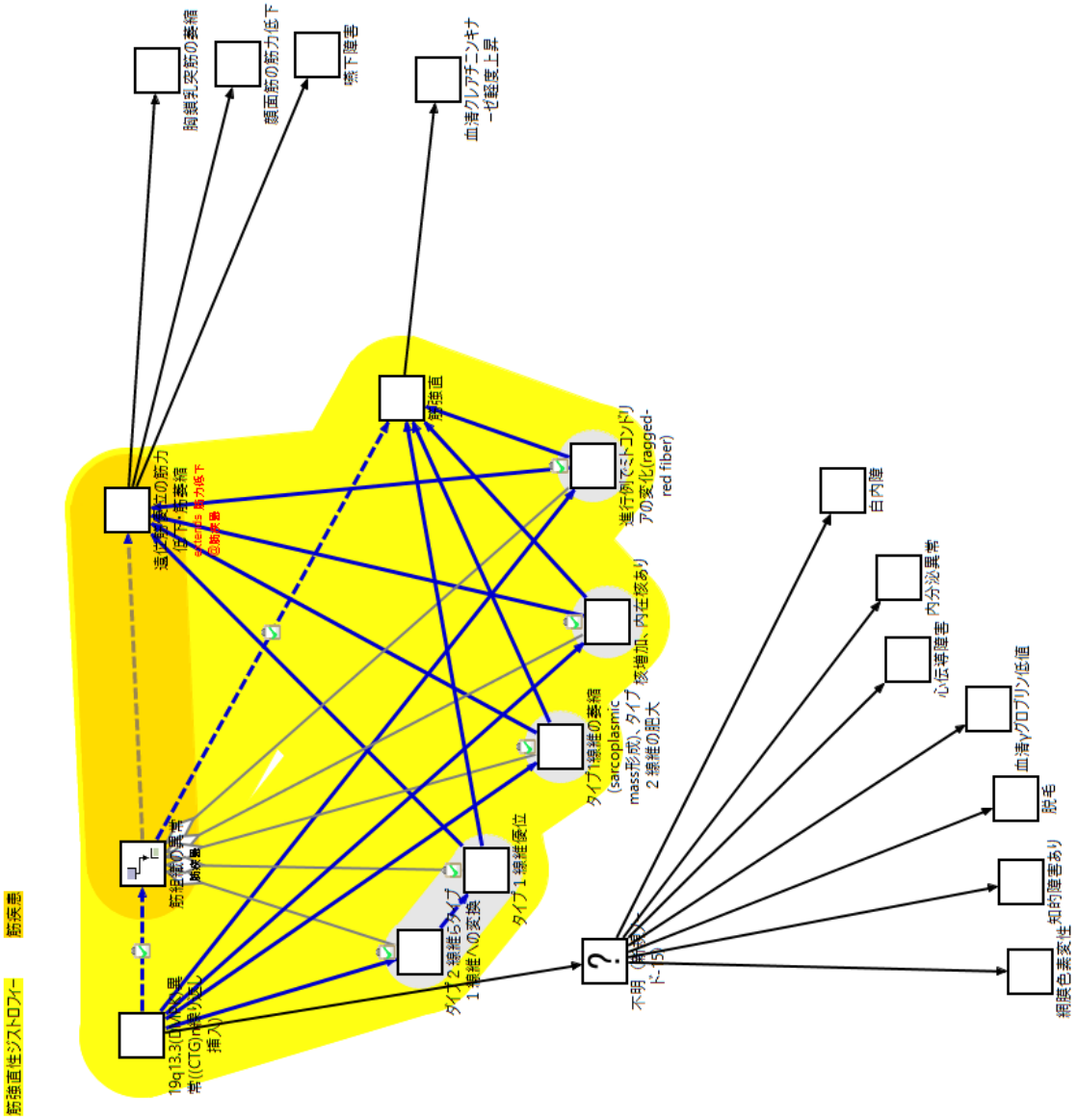

Figure 36. 神経内科:筋強直性ジストロフィー

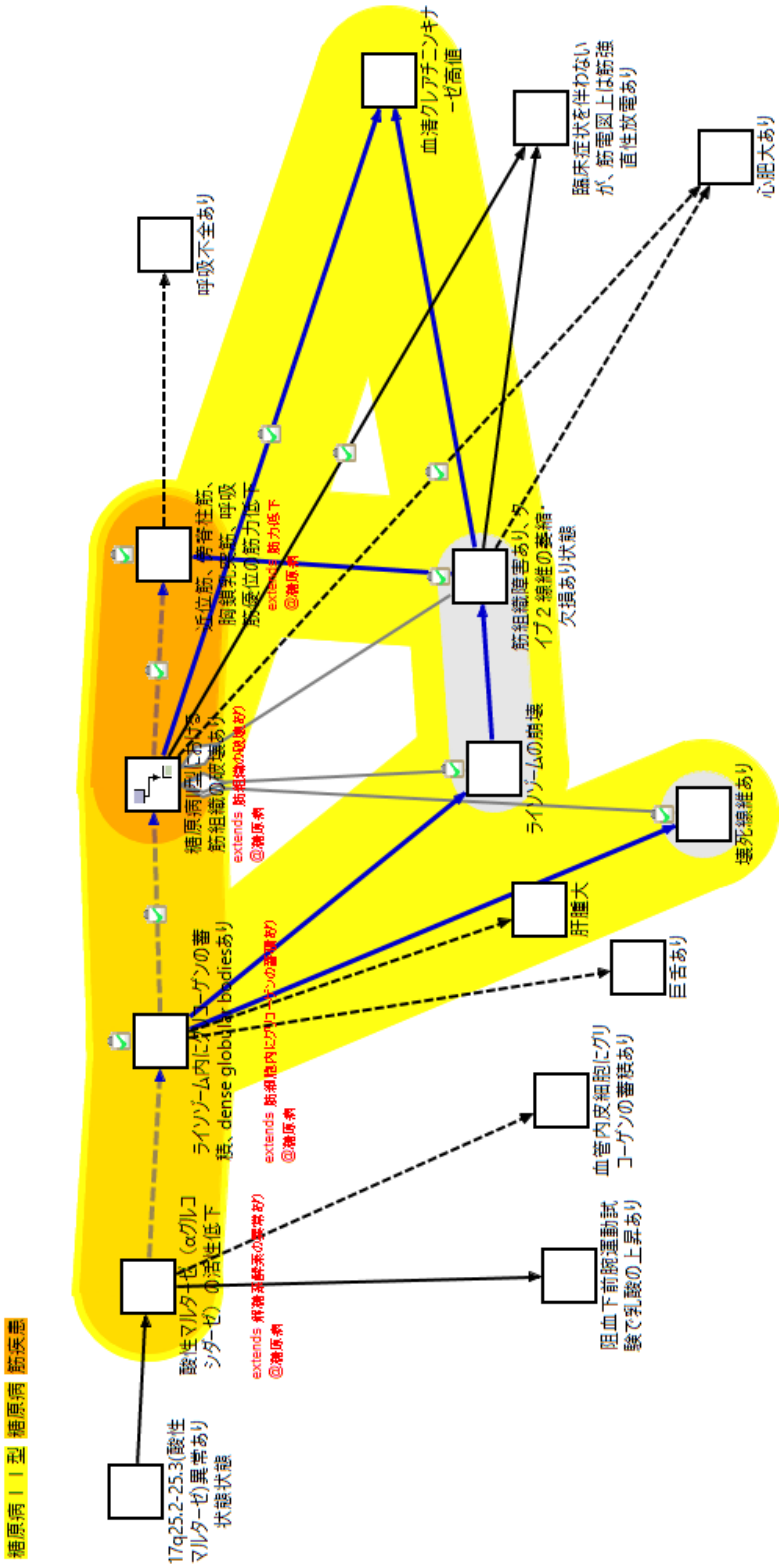

Figure 37. 神経内科:糖原病ＩＩ型

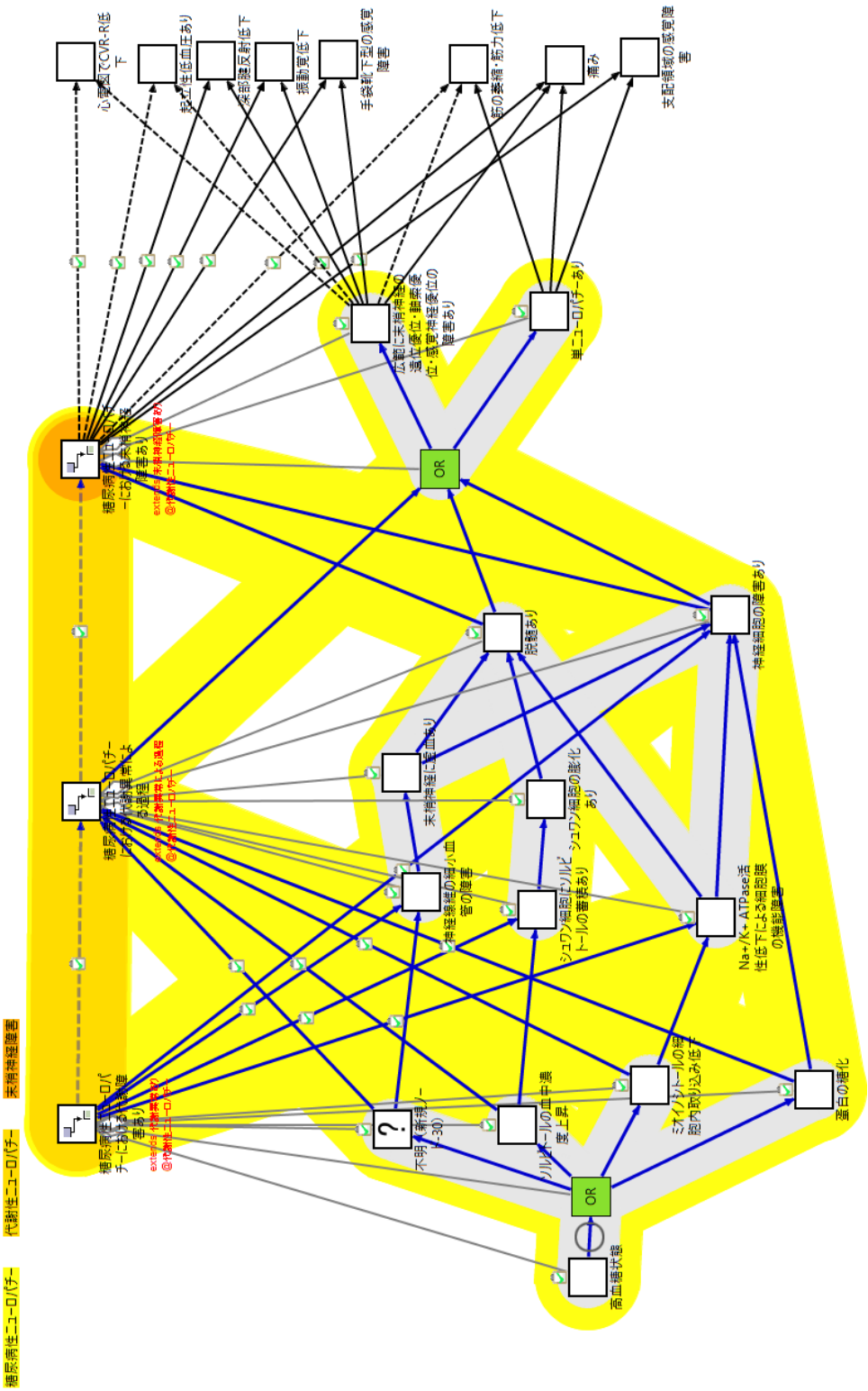
糖尿病性ニューロパチー
代謝性ニューロパチー
末梢神経障害
糖尿病性ニューロパチー
糖尿病性ニューロパチー
糖尿病性ニューロパチー

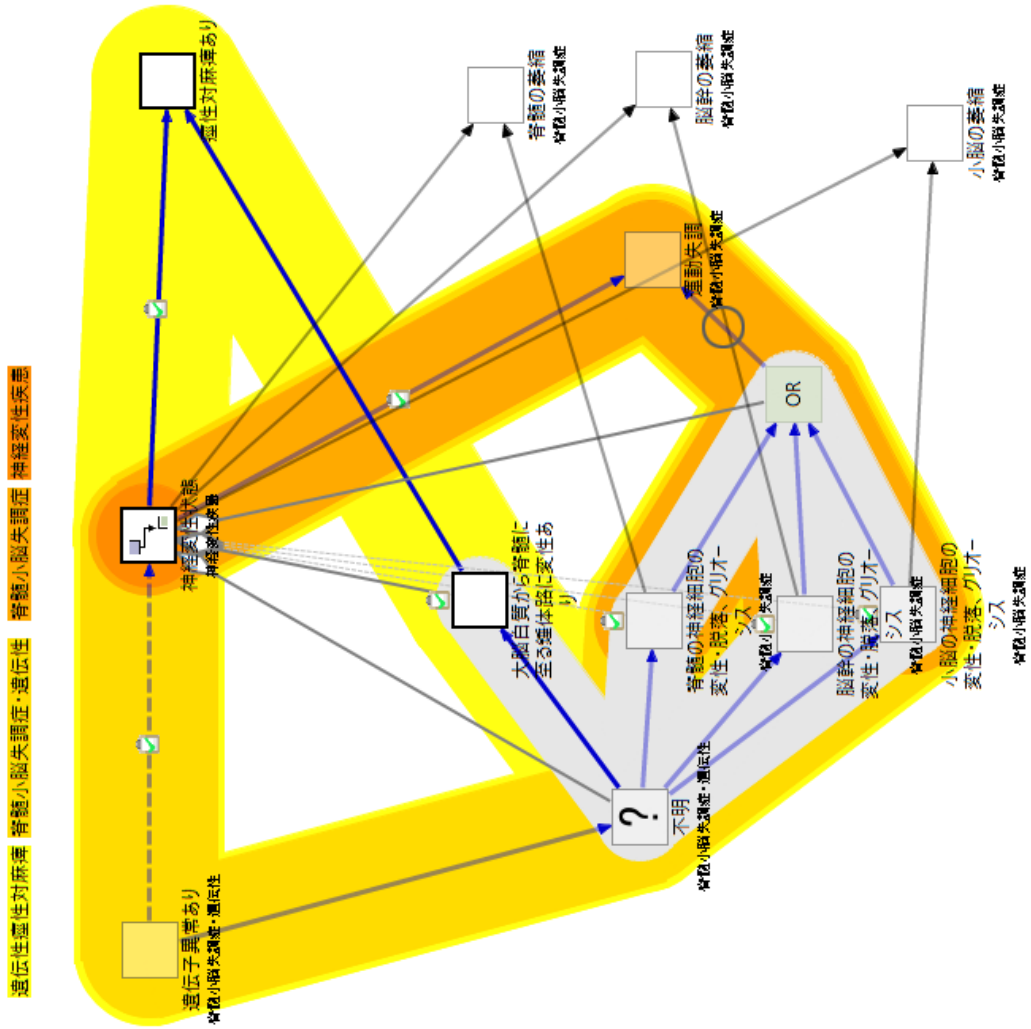

Figure 39. 神経内科:遺伝性痙性対麻痺

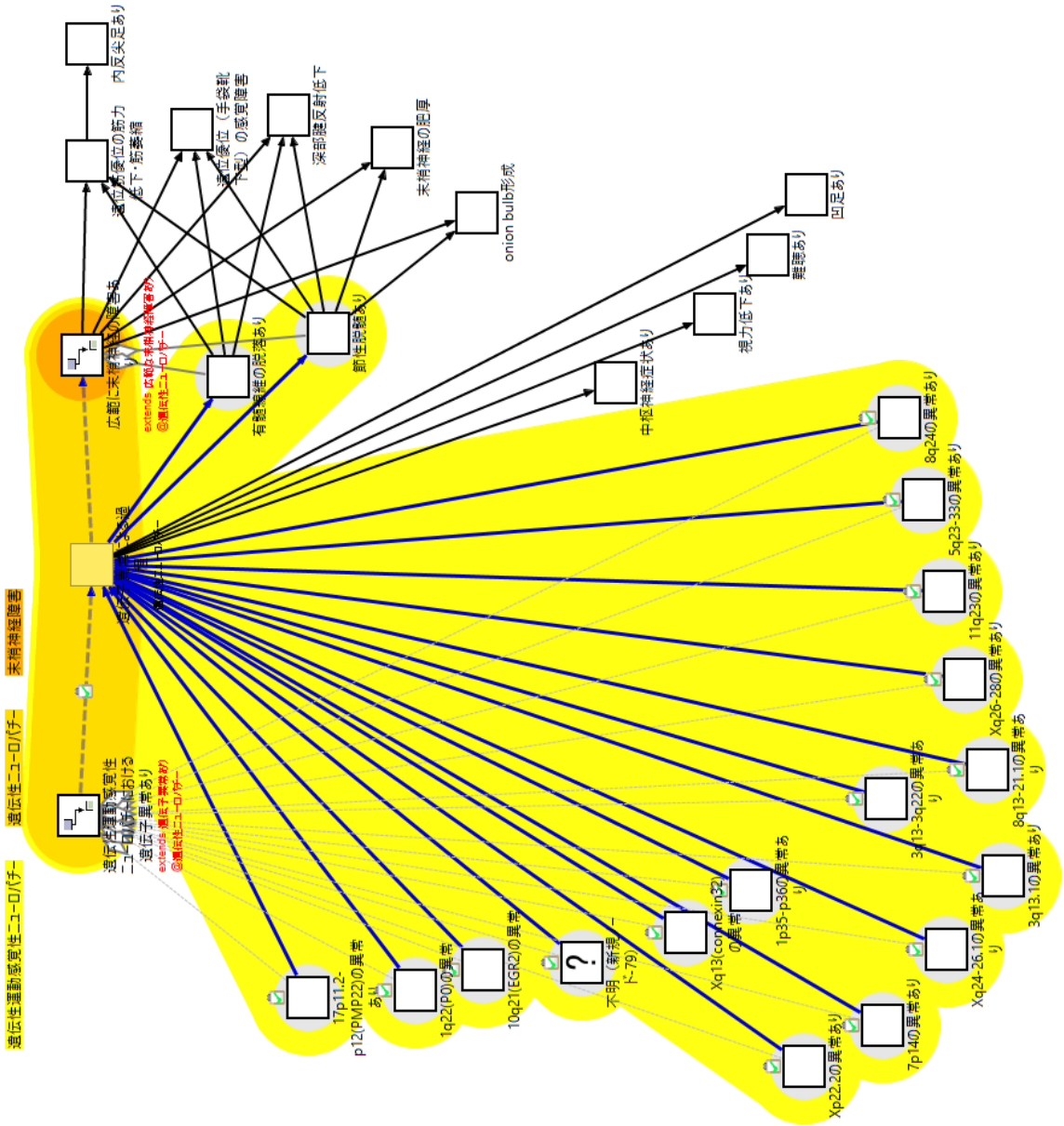

Figure 40. 神経内科:遺伝性運動感覚性ニューロパチー

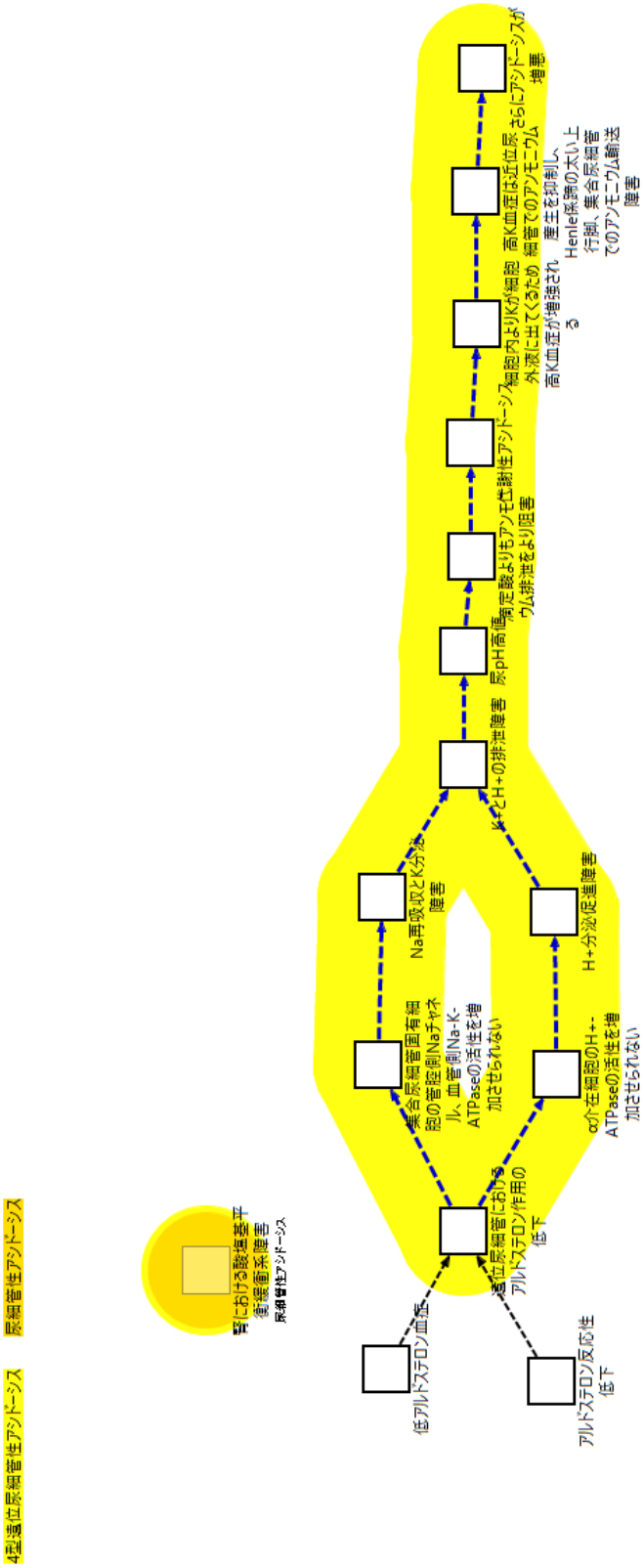

Figure 41. 腎臓内分泌内科:4 型遠位尿細管性アシドーシス

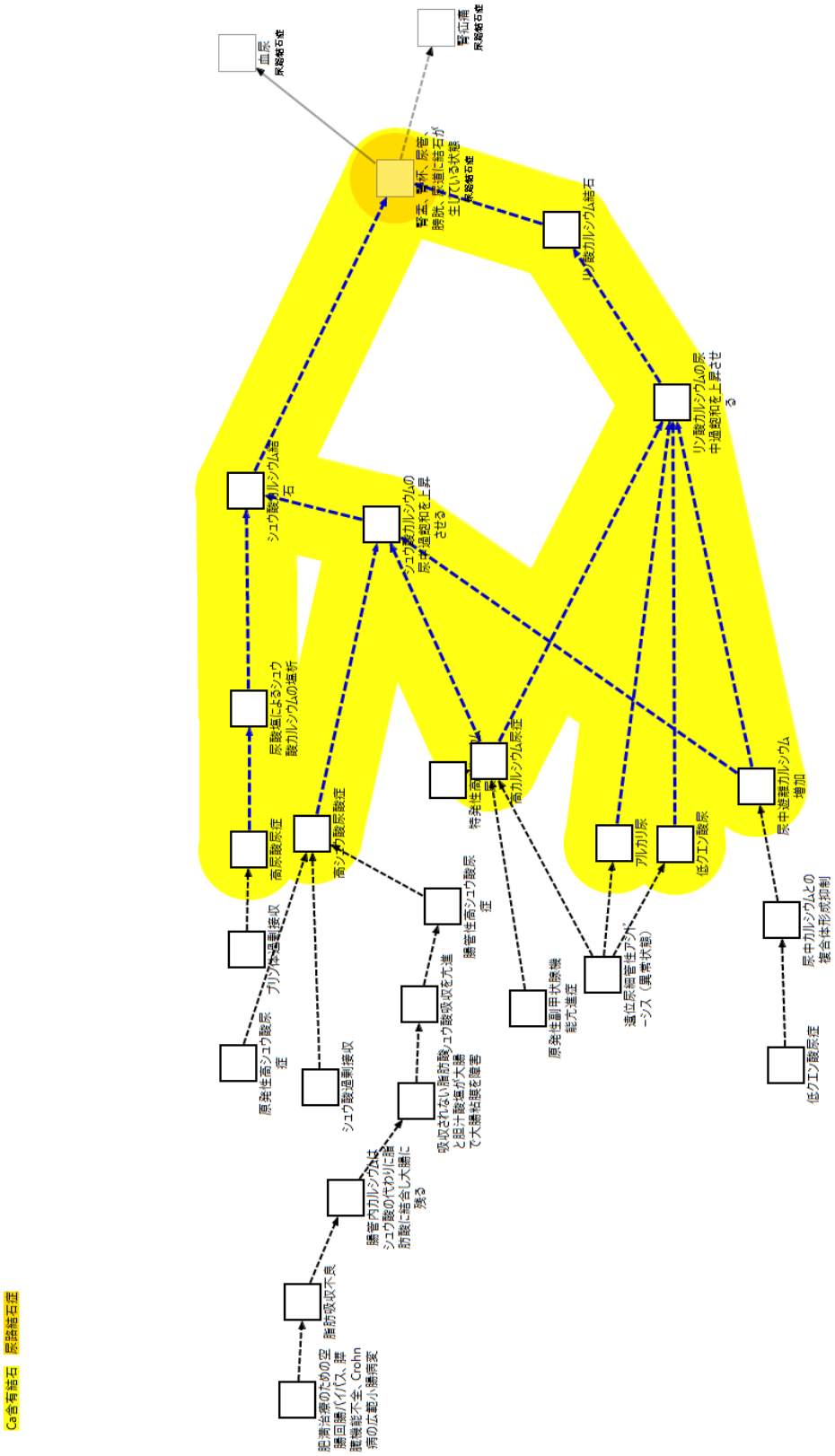

Figure 42. 腎臓内分泌内科:Ca 含有結石

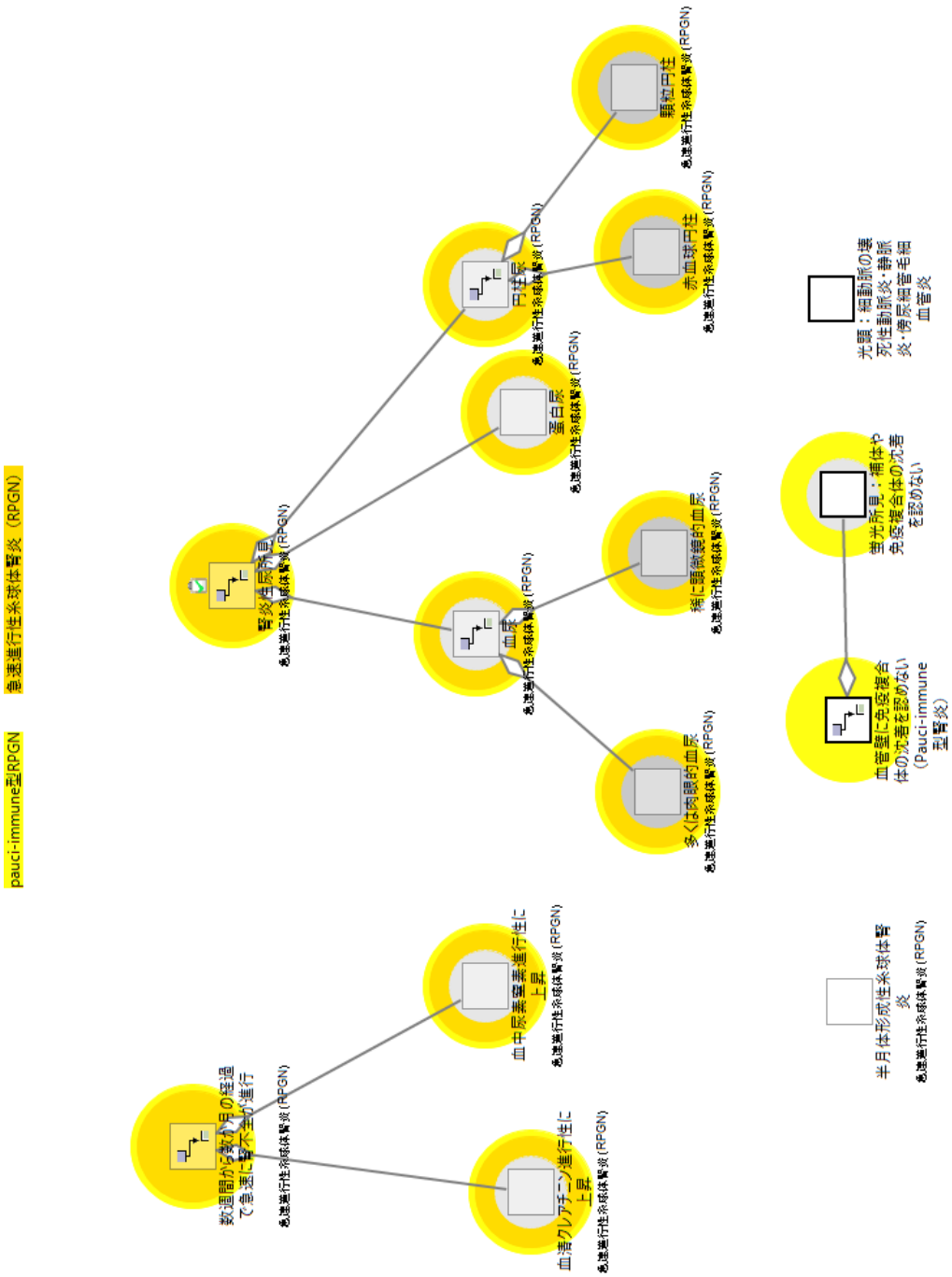

Figure 43. 腎臓内分泌内科:pauci-immune 型 RPGN

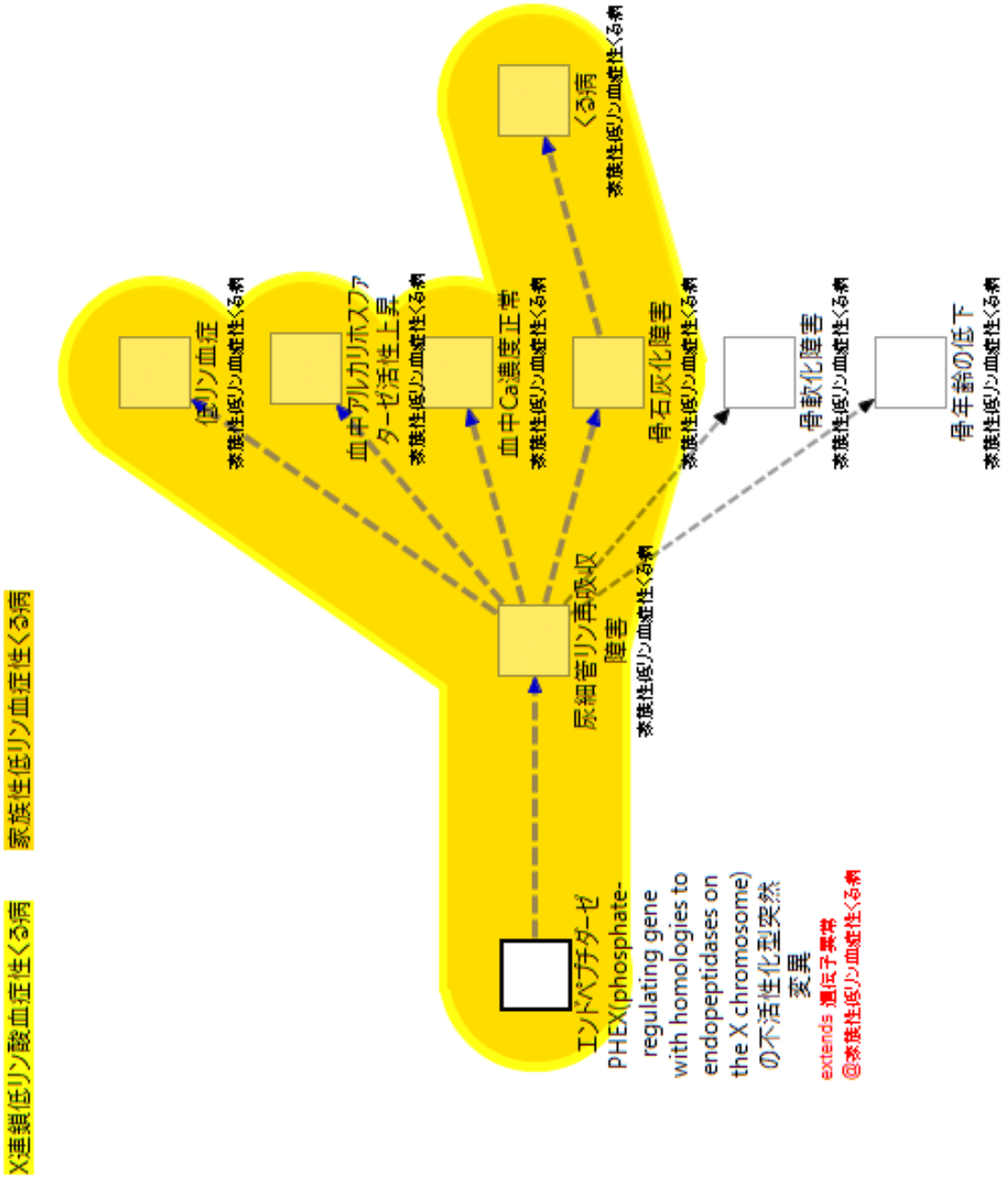

Figure 44. 腎臓内分泌内科:X 連鎖低リン酸血症性くる病

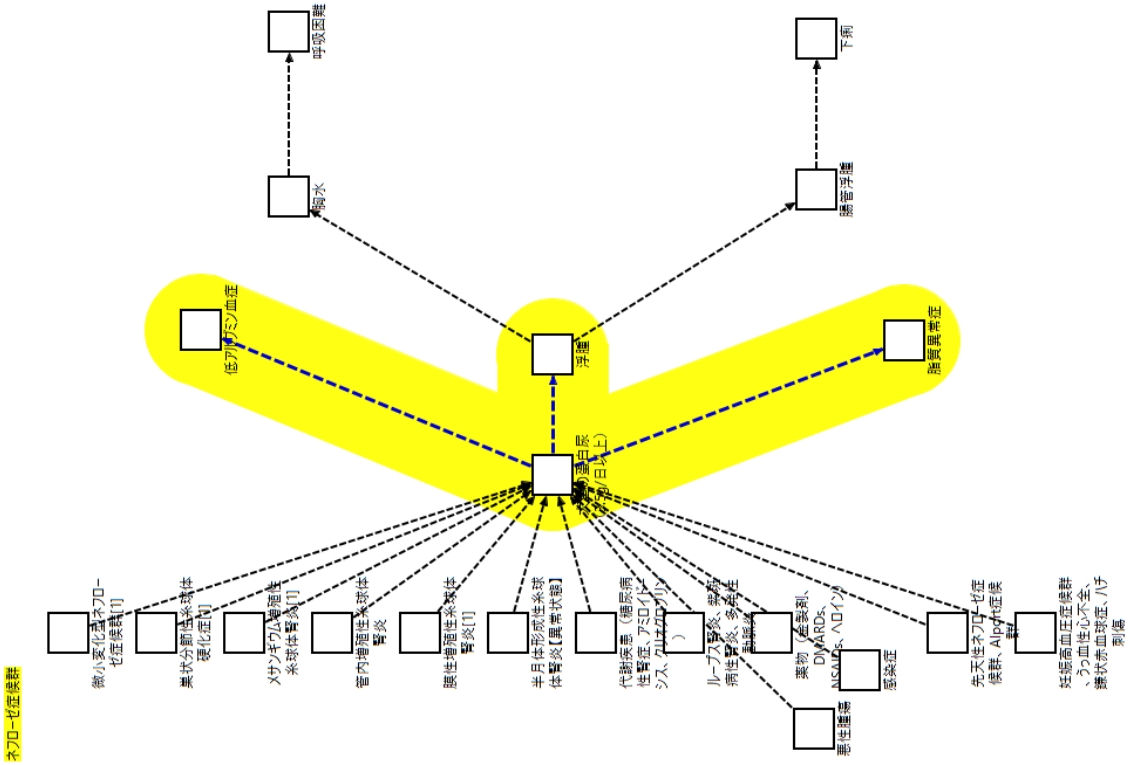

Figure 45. 腎臓内分泌内科:ネフローゼ症候群

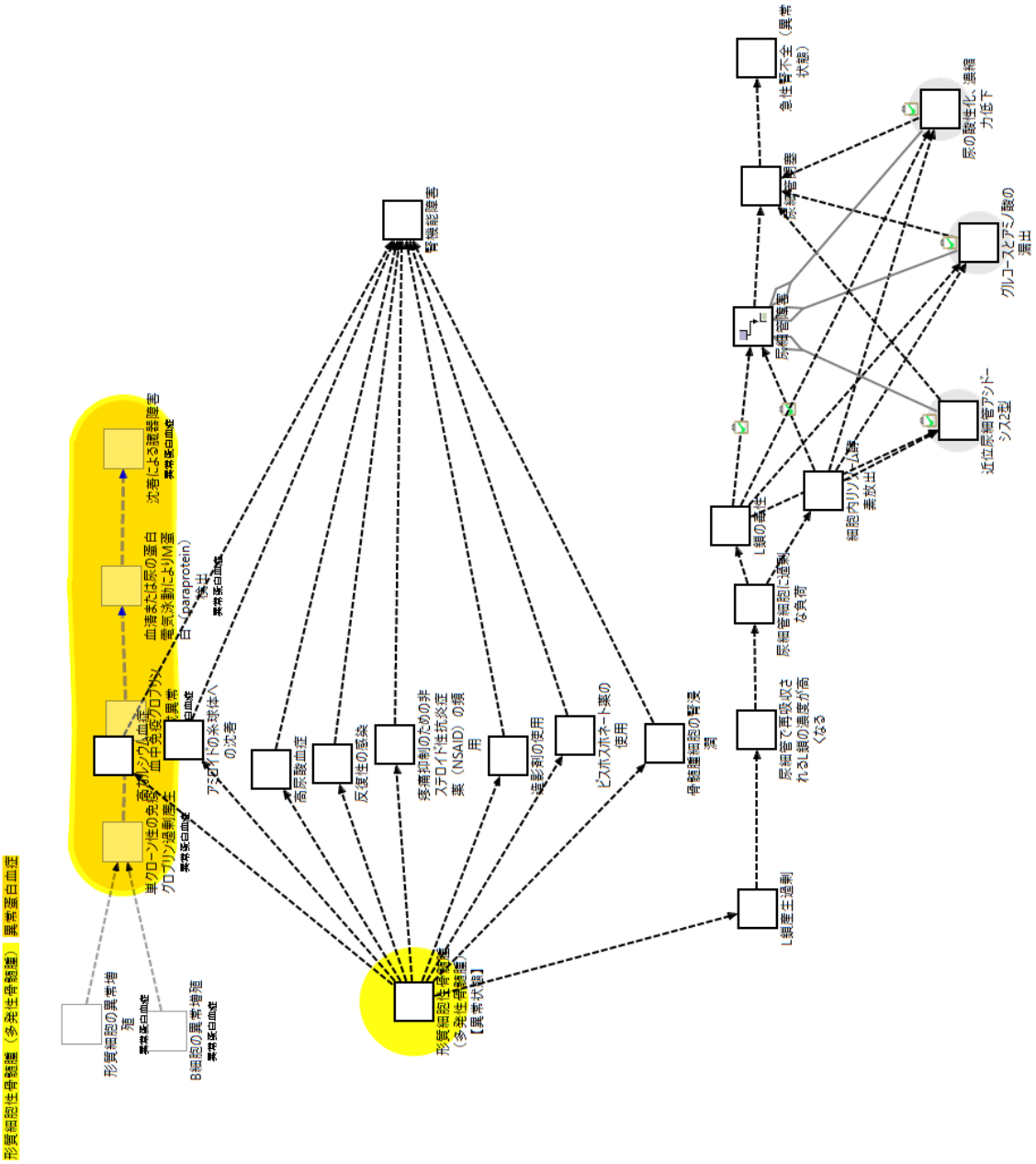

Figure 46. 腎臓内分泌内科:形質細胞性骨髄腫（多発性骨髄腫）

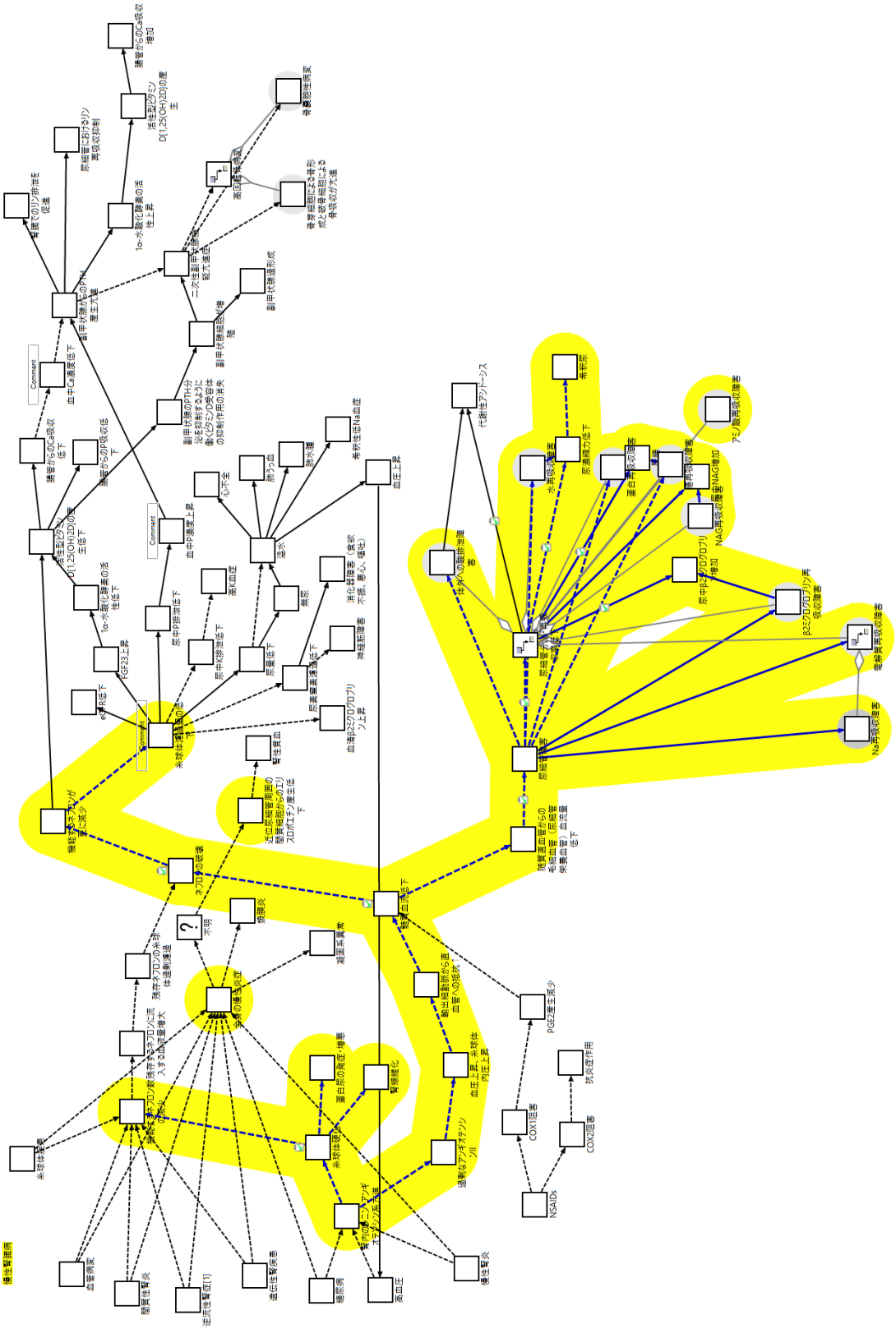

Figure 47. 腎臓内分泌内科:慢性腎臓病

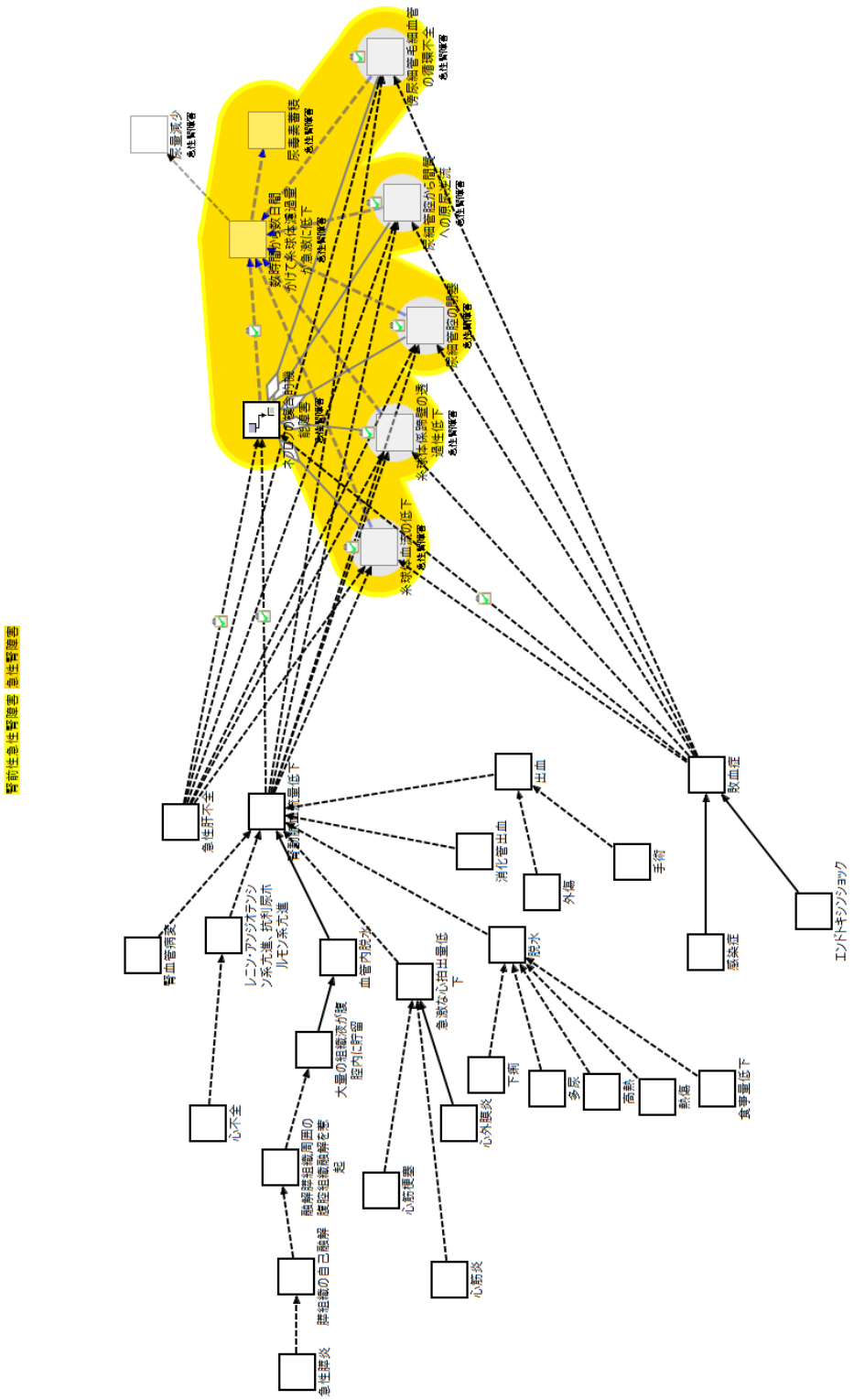

Figure 48. 腎臓内分泌内科:腎前性急性腎障害

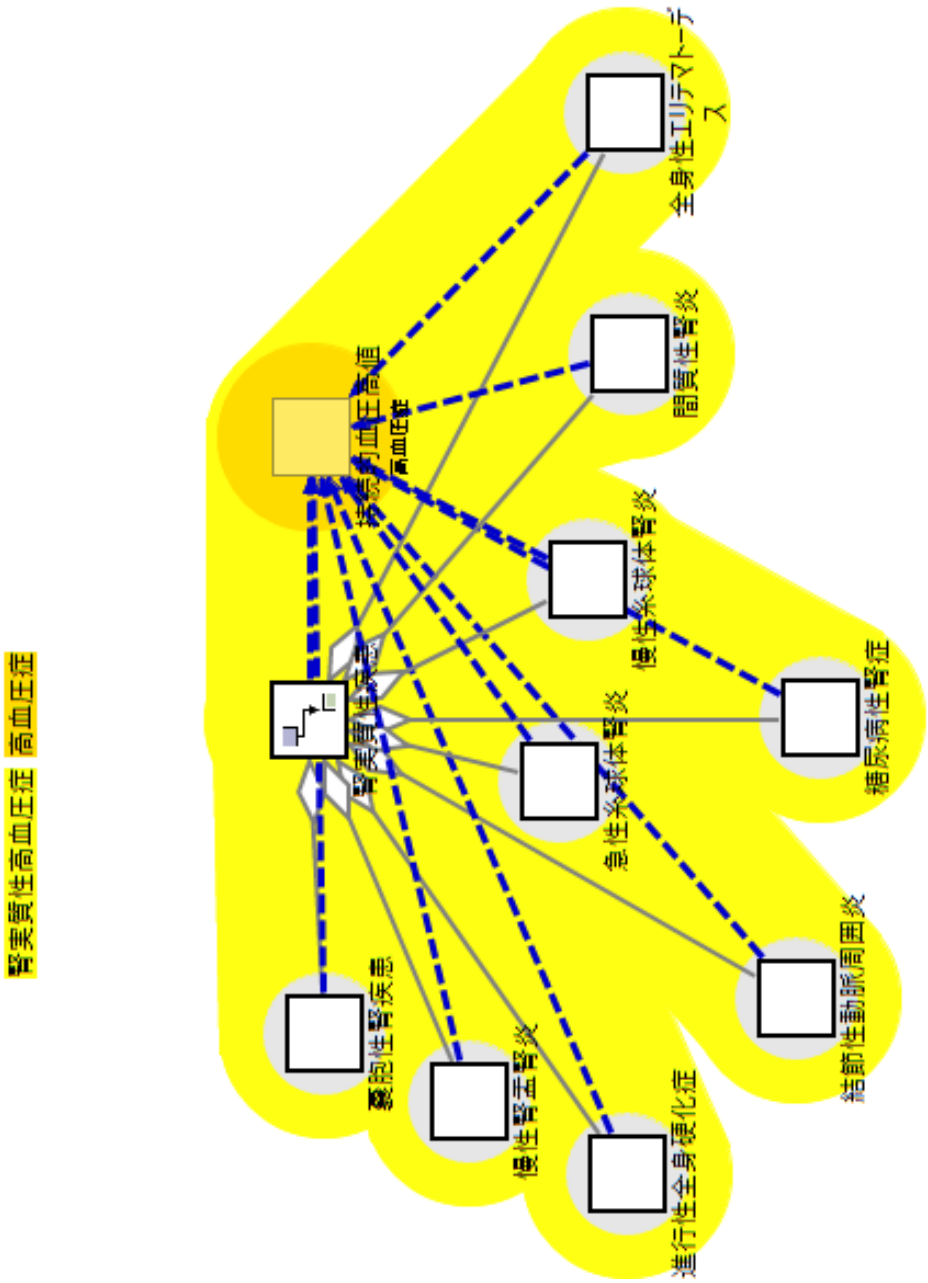
腎実質性高血圧症
高血圧症
腎実質性高血圧症
腎実質性高血圧症
腎実質性

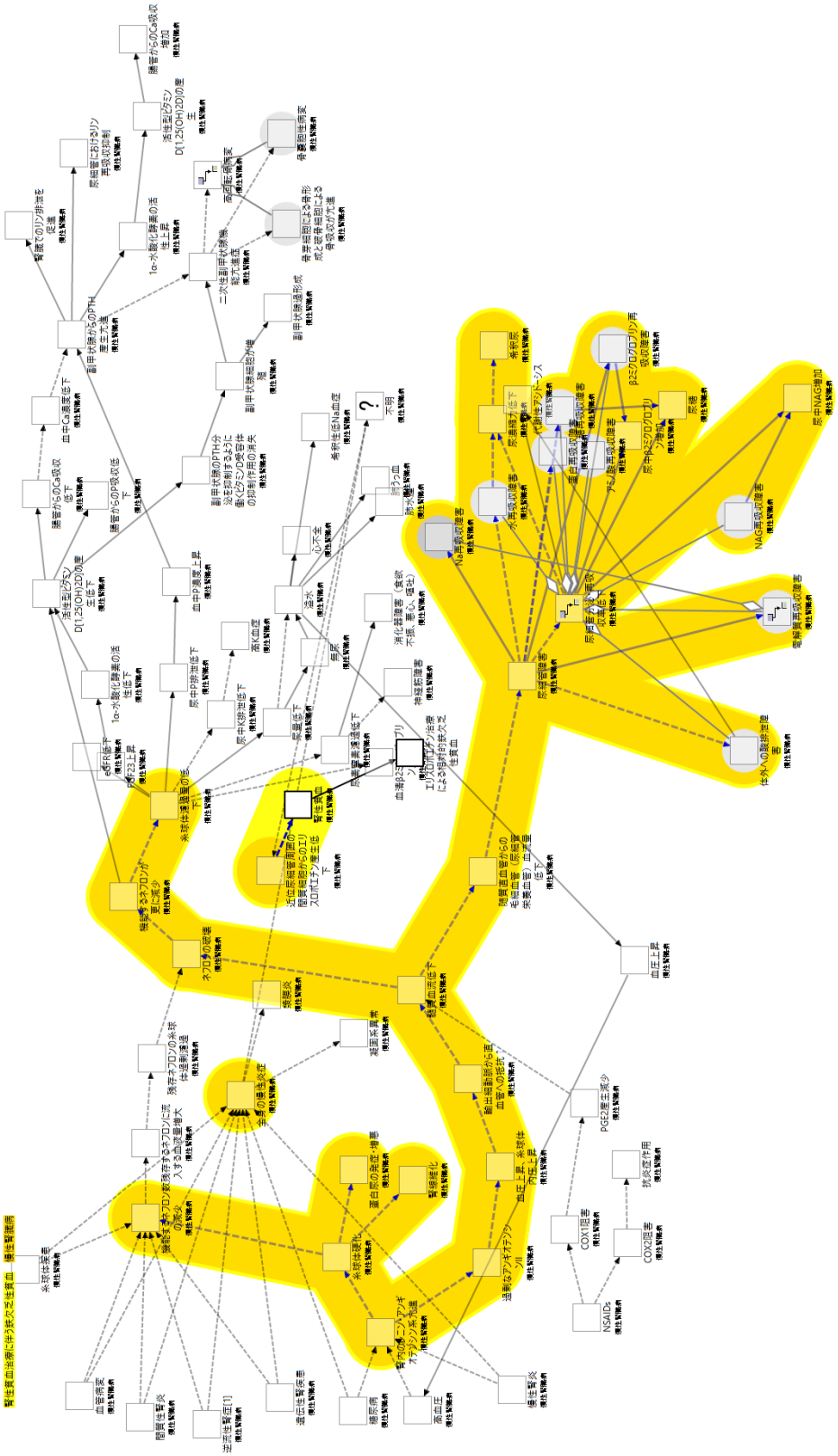

Figure 50. 腎臓内分泌内科:腎性貧血治療に伴う鉄欠乏性貧血

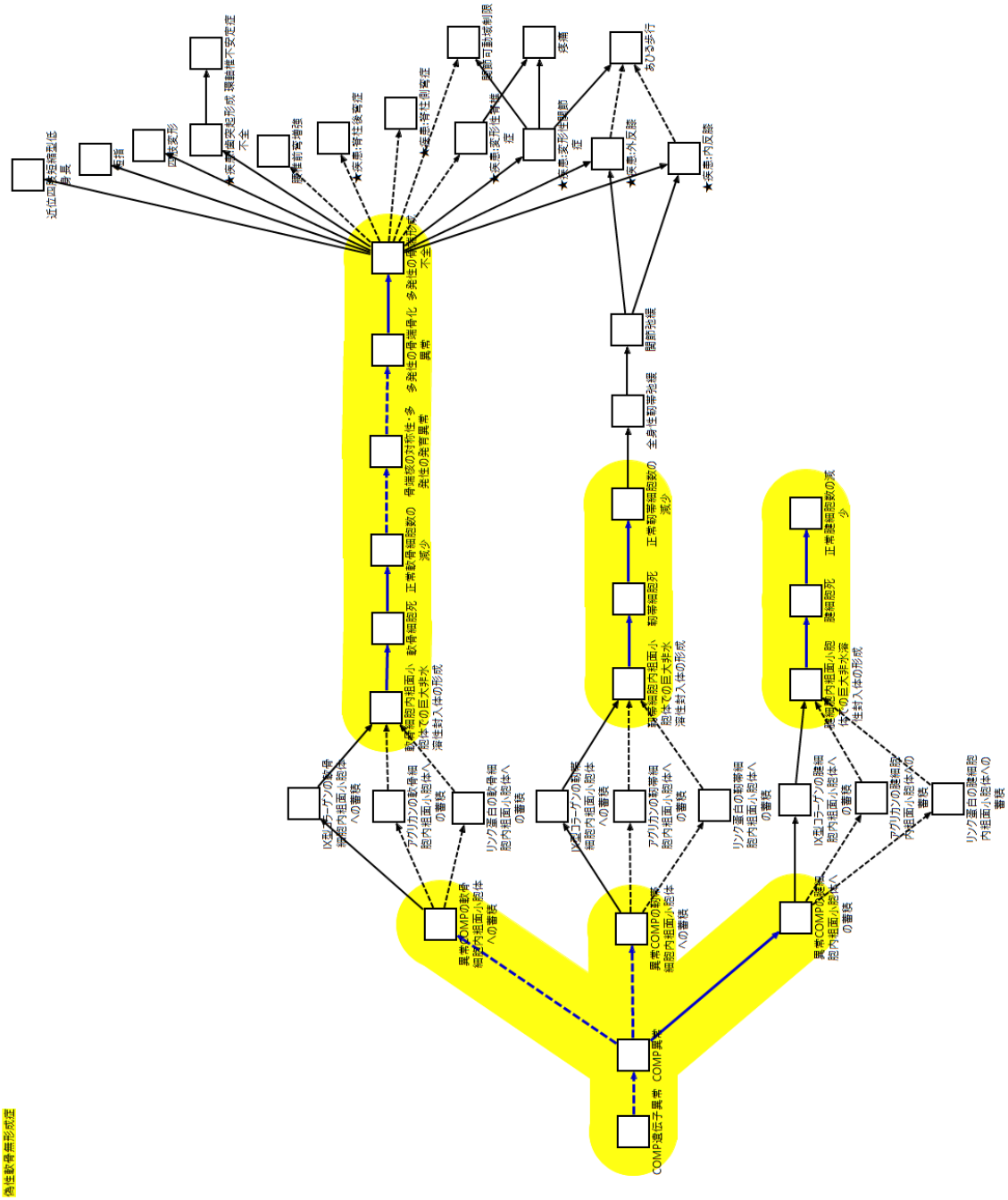

Figure 51. 整形外科:偽性軟骨無形成症

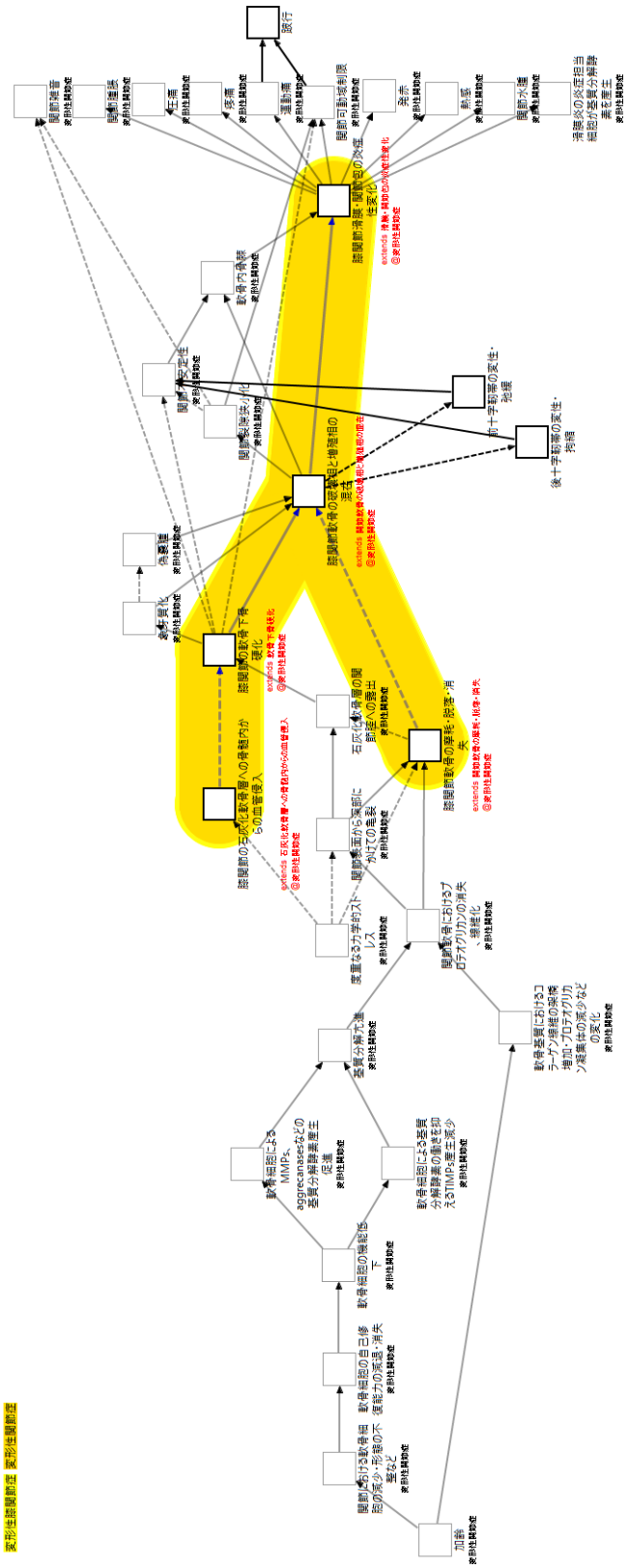

Figure 52. 整形外科:変形性膝関節症

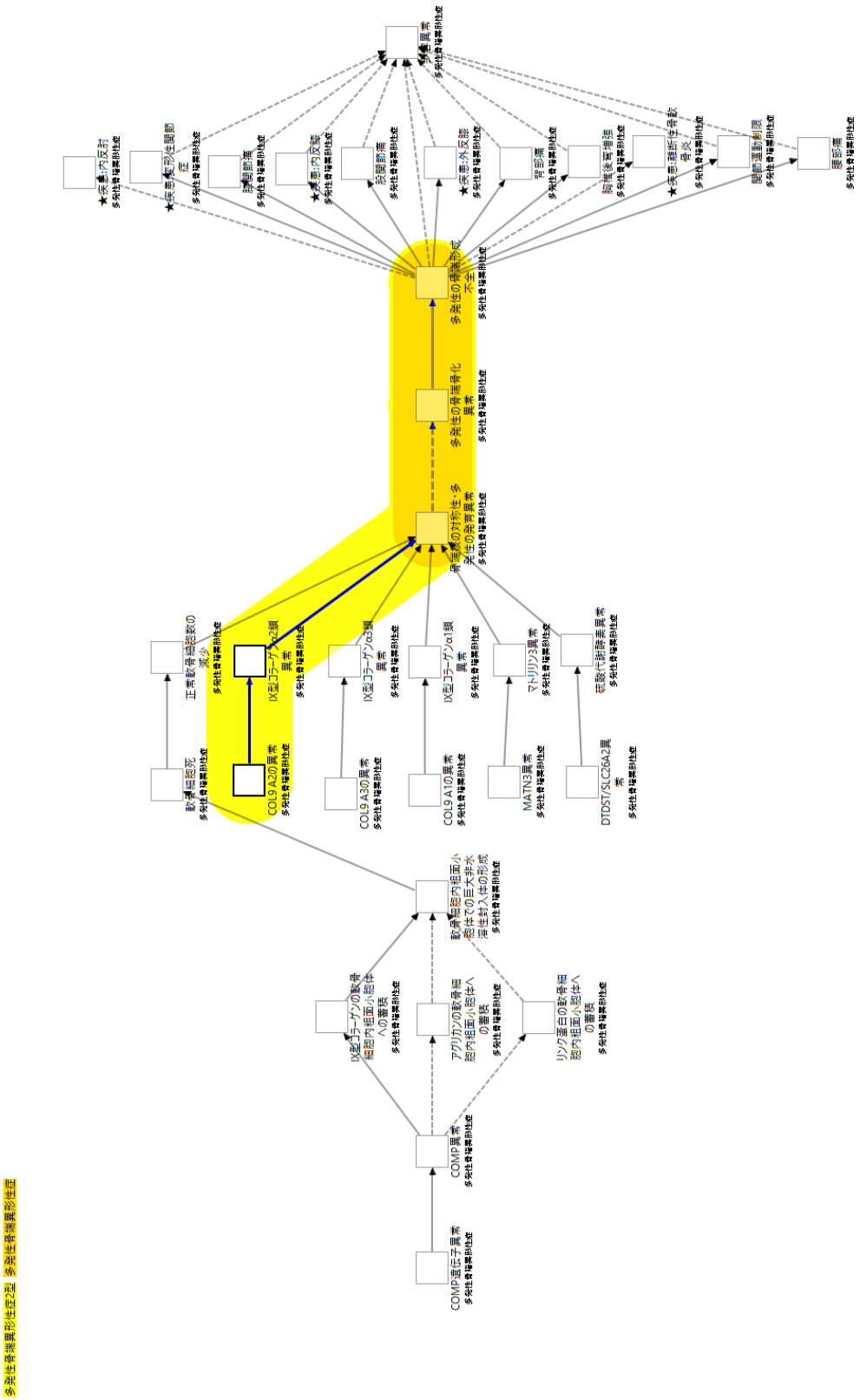

Figure 53. 整形外科:多発性骨端異形性症 2 型

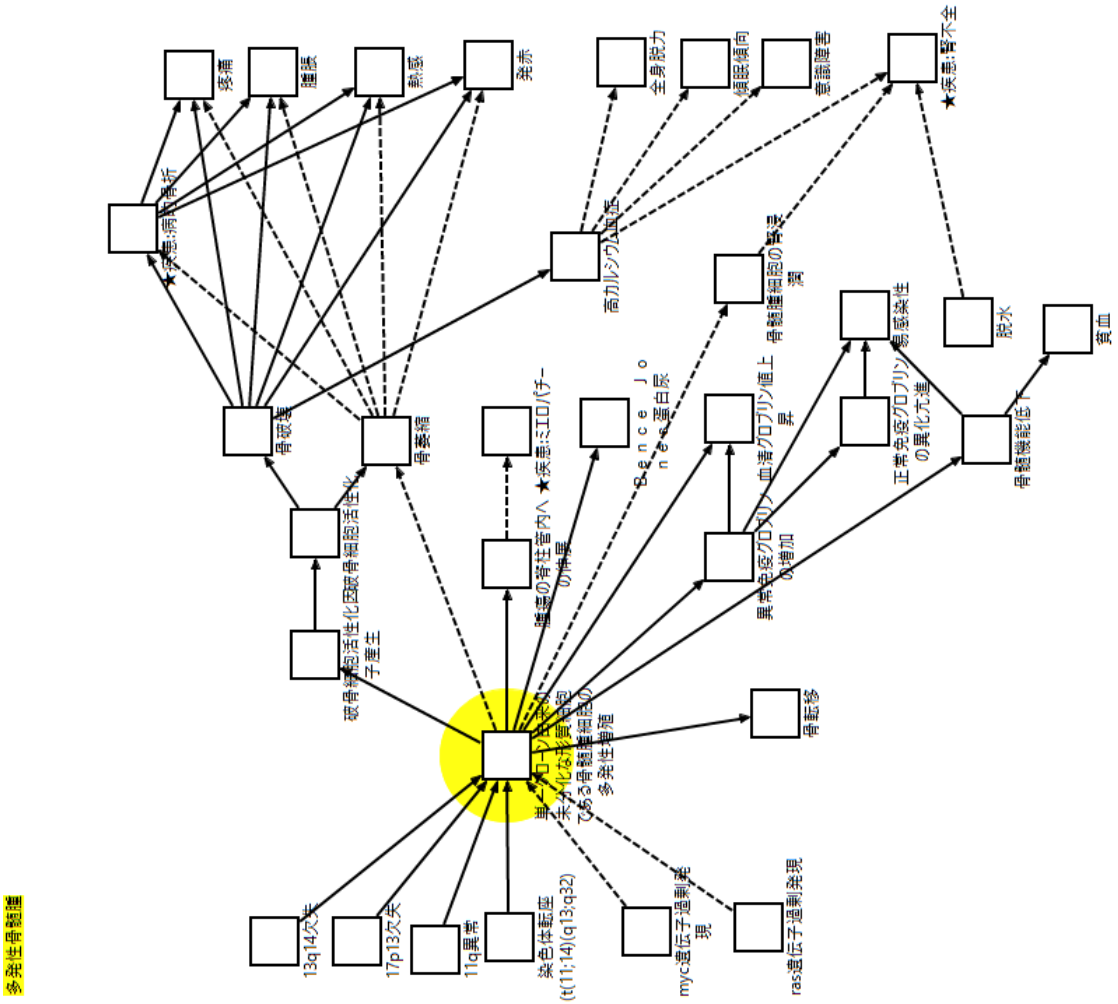

Figure 54. 整形外科:多発性骨髄腫

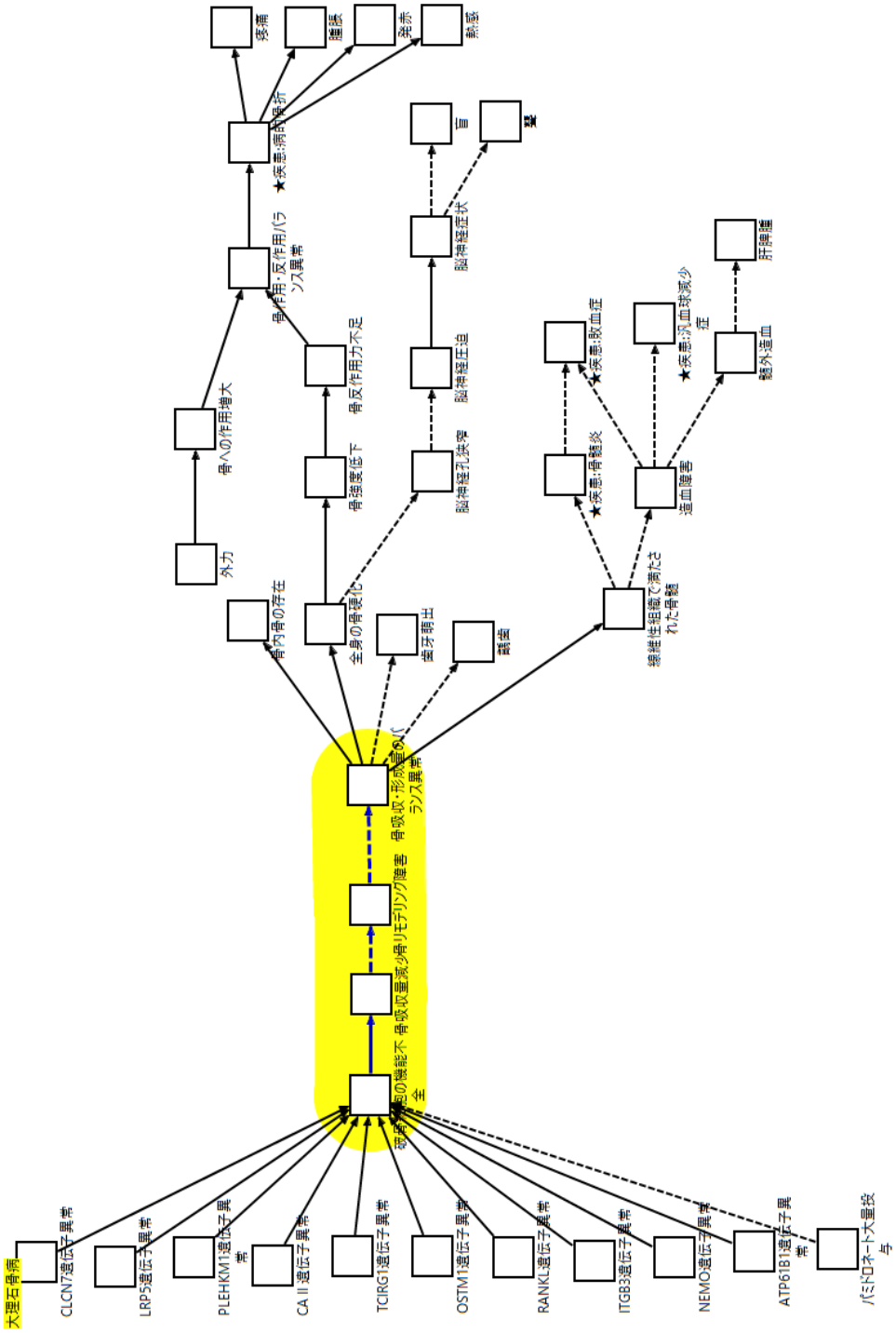

Figure 55. 整形外科:大理石骨病

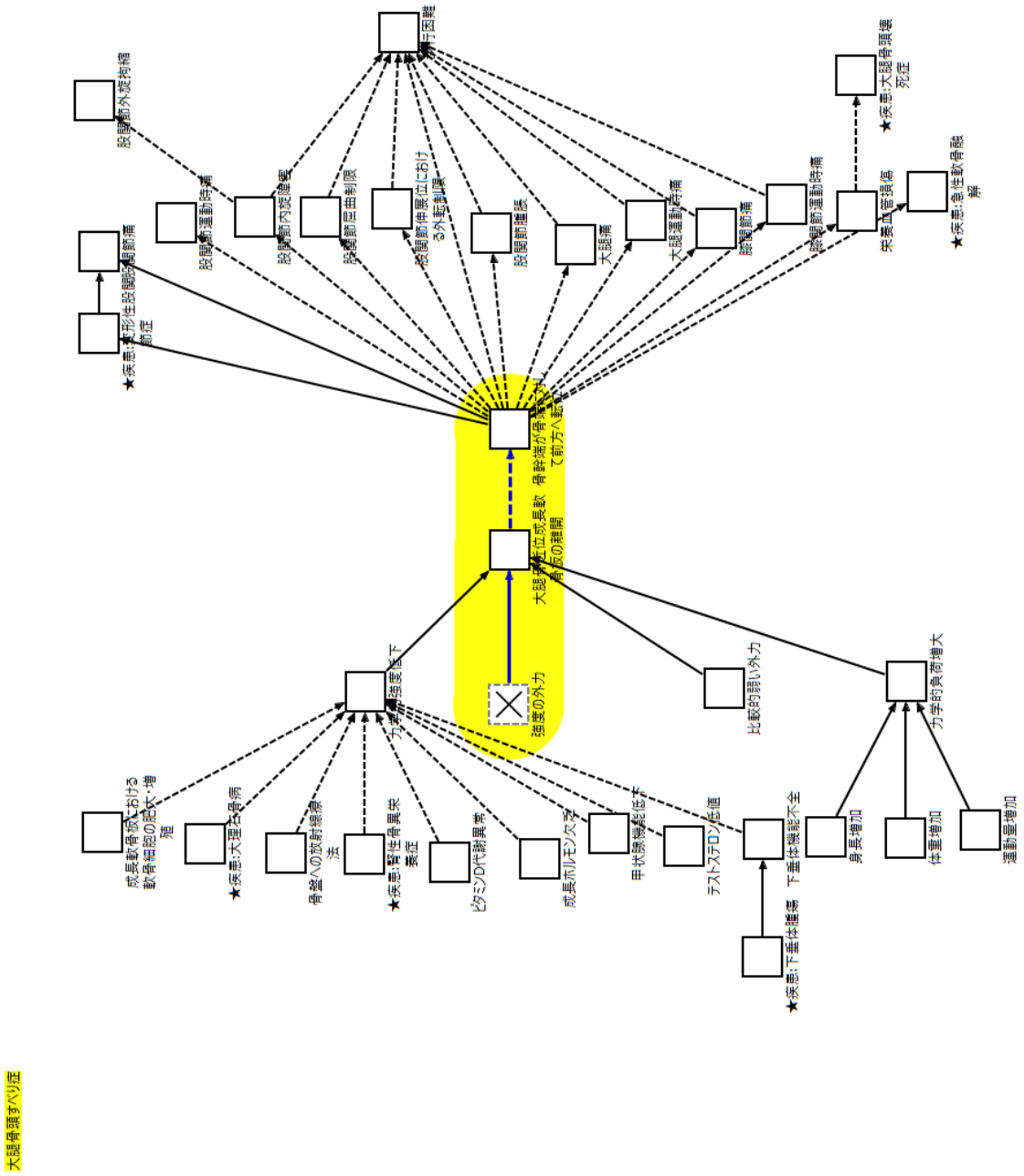

Figure 56. 整形外科:大腿骨頭すべり症

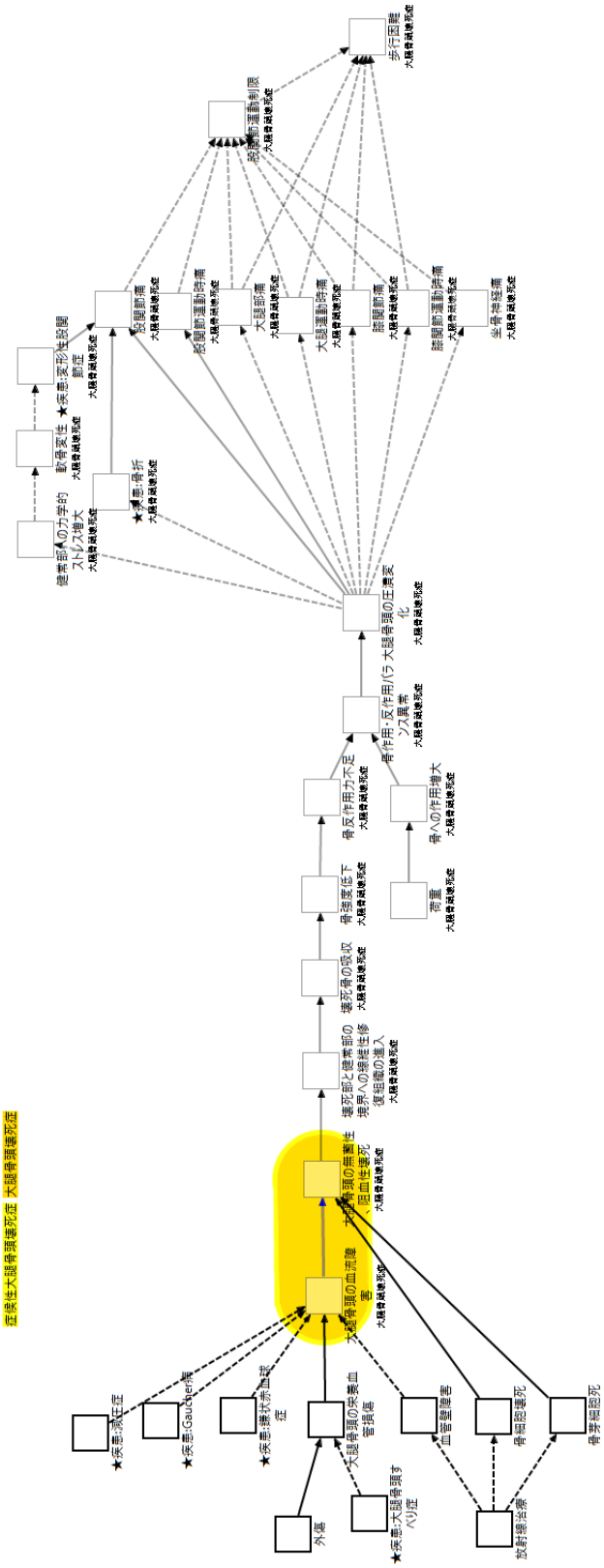

Figure 57. 整形外科:症候性大腿骨頭壊死症

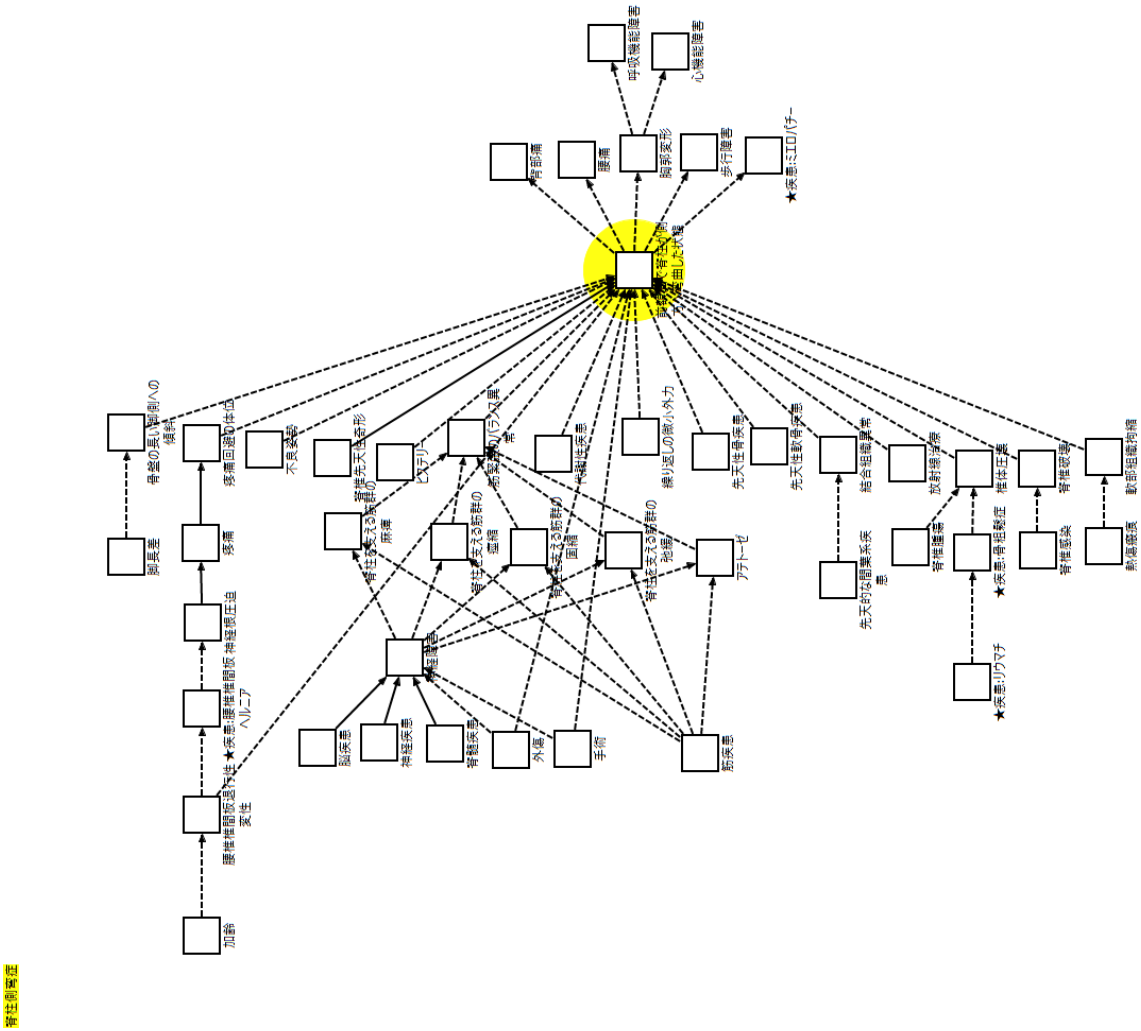

Figure 58. 整形外科:脊柱側弯症

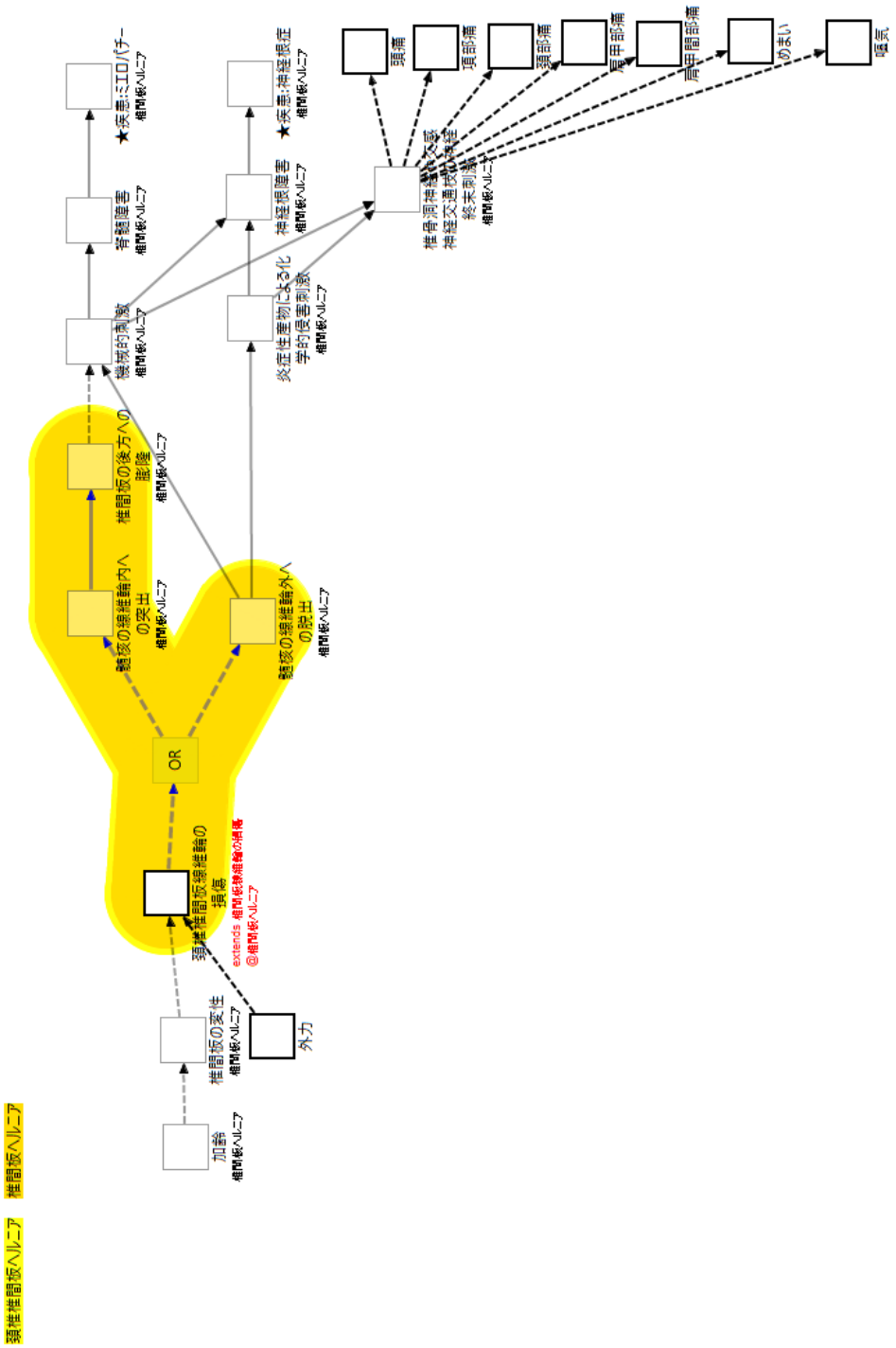

Figure 59. 整形外科:頸椎椎間板ヘルニア

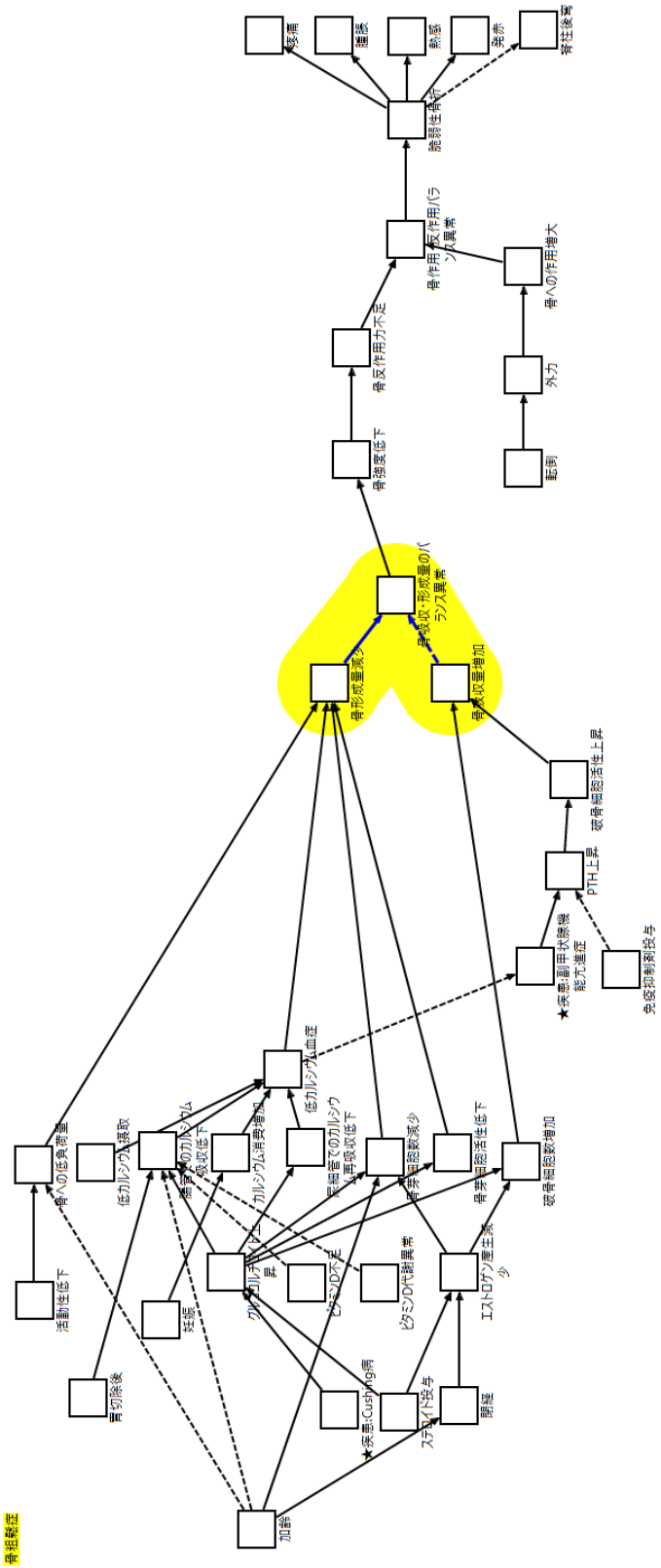

Figure 60. 整形外科:骨粗鬆症

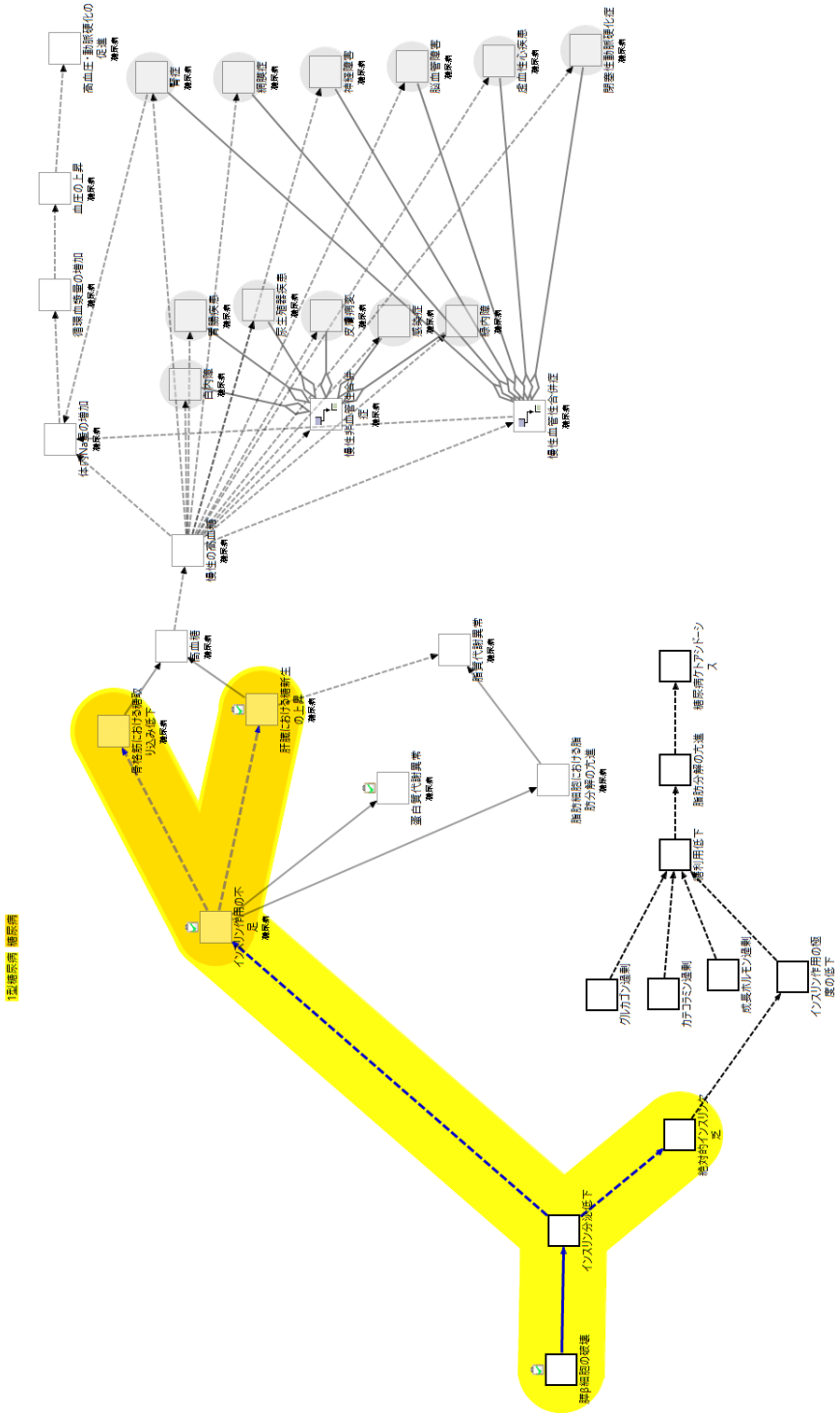

Figure 61. 糖尿病代謝内科:1 型糖尿病

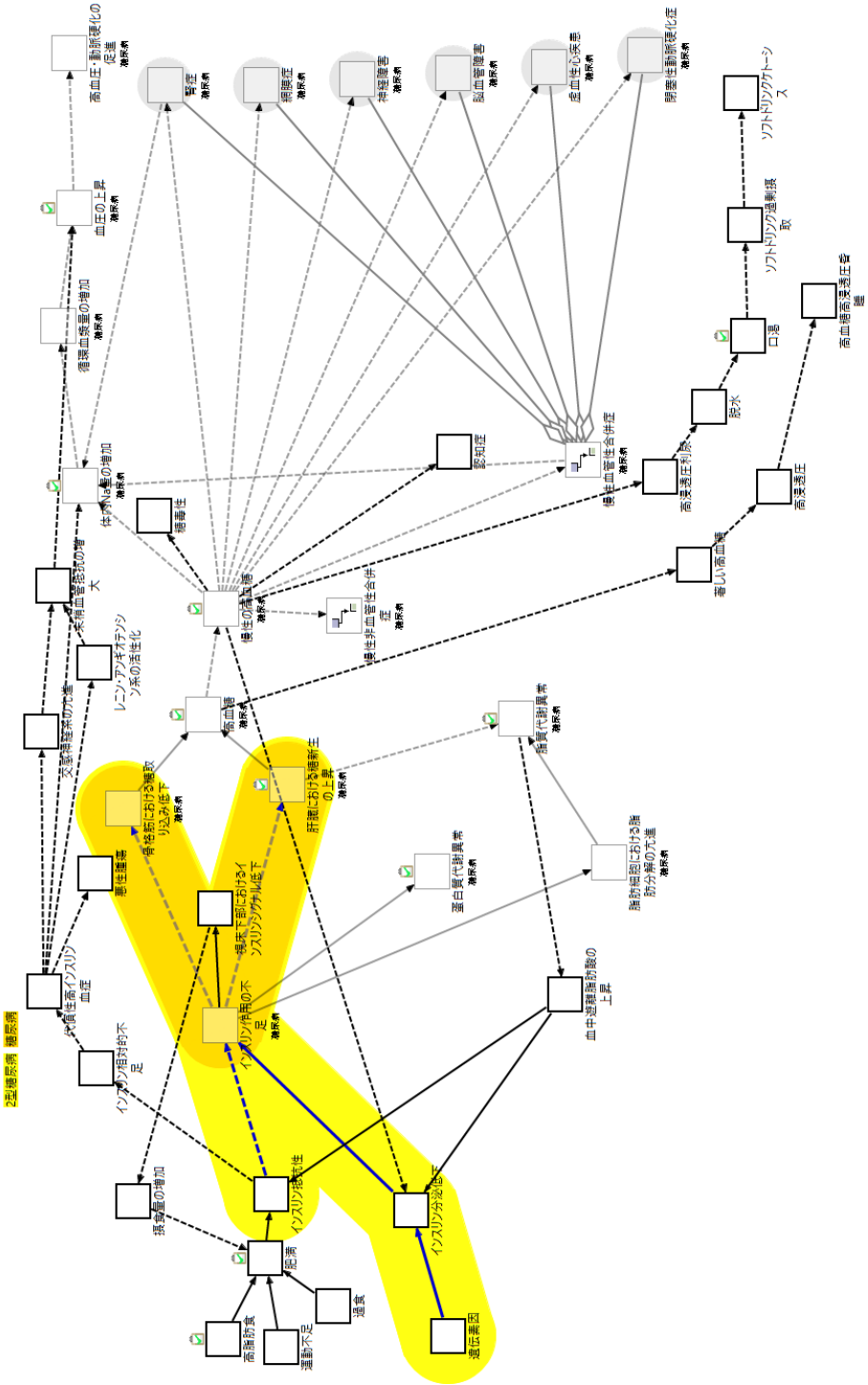
2型糖尿病 糖尿病
代謝性系インスリン血症
インスリン相対的不足
交感神経系の亢進
レニン・アンギオテンシン系の活性化
骨格筋における糖取り込み低下
肝臓における糖新生の上昇
インスリン作用の不足
視床下部におけるインスリンシグナル低下
インスリン抵抗性
インスリン分泌低下
遺伝素因
遺伝
運動不足
高脂肪食
摂食量の増加
肥満
体内Na量の増加
血圧の上昇
高血圧・動脈硬化の促進
腎臓血管収縮の増大
腎臓血管拡張の増大
腎臓血管の増加
腎臓の肥大
腎臓の機能低下
腎臓血管性合併症
腎臓血管性合併症
腎臓血管性合併症

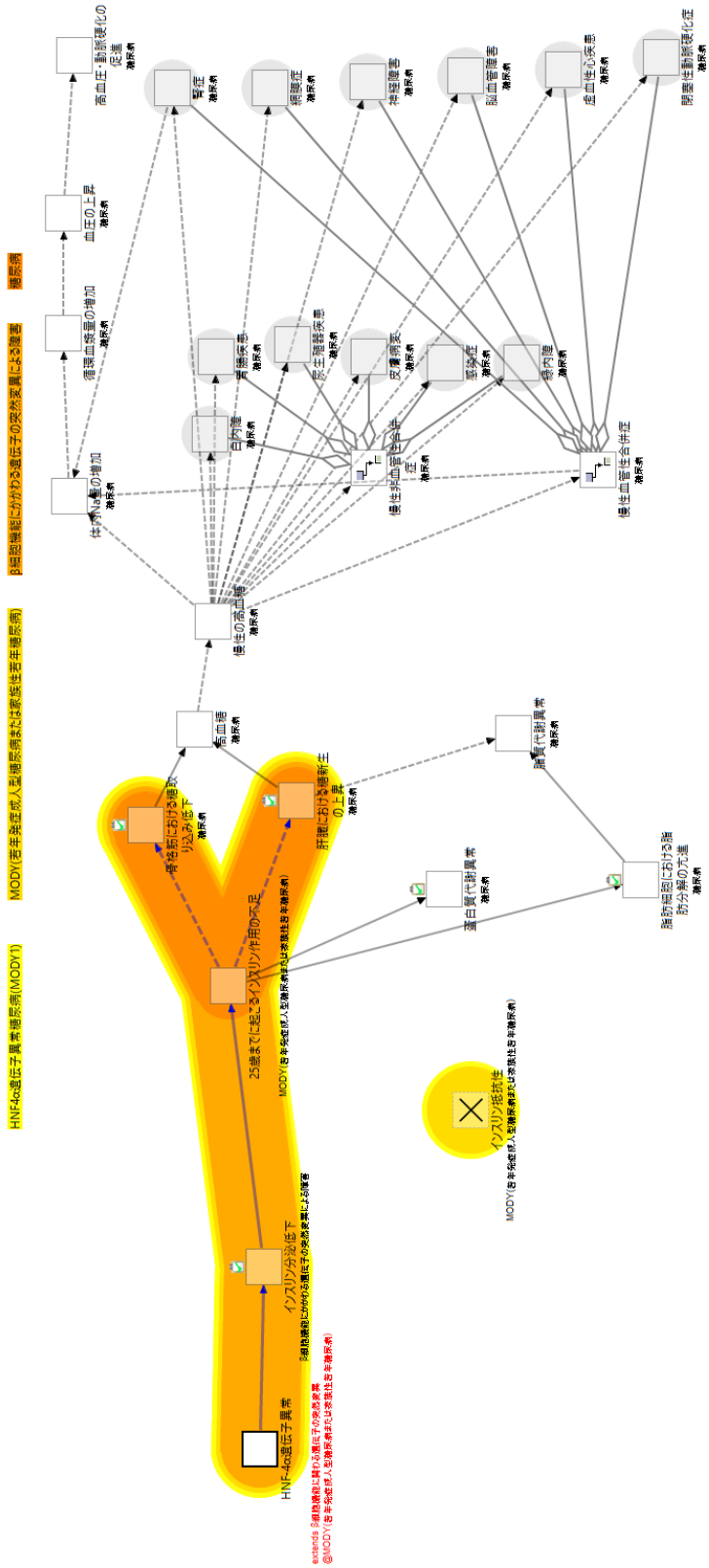

Figure 63. 糖尿病代謝内科:HNF4α遺伝子異常糖尿病(MODY1)

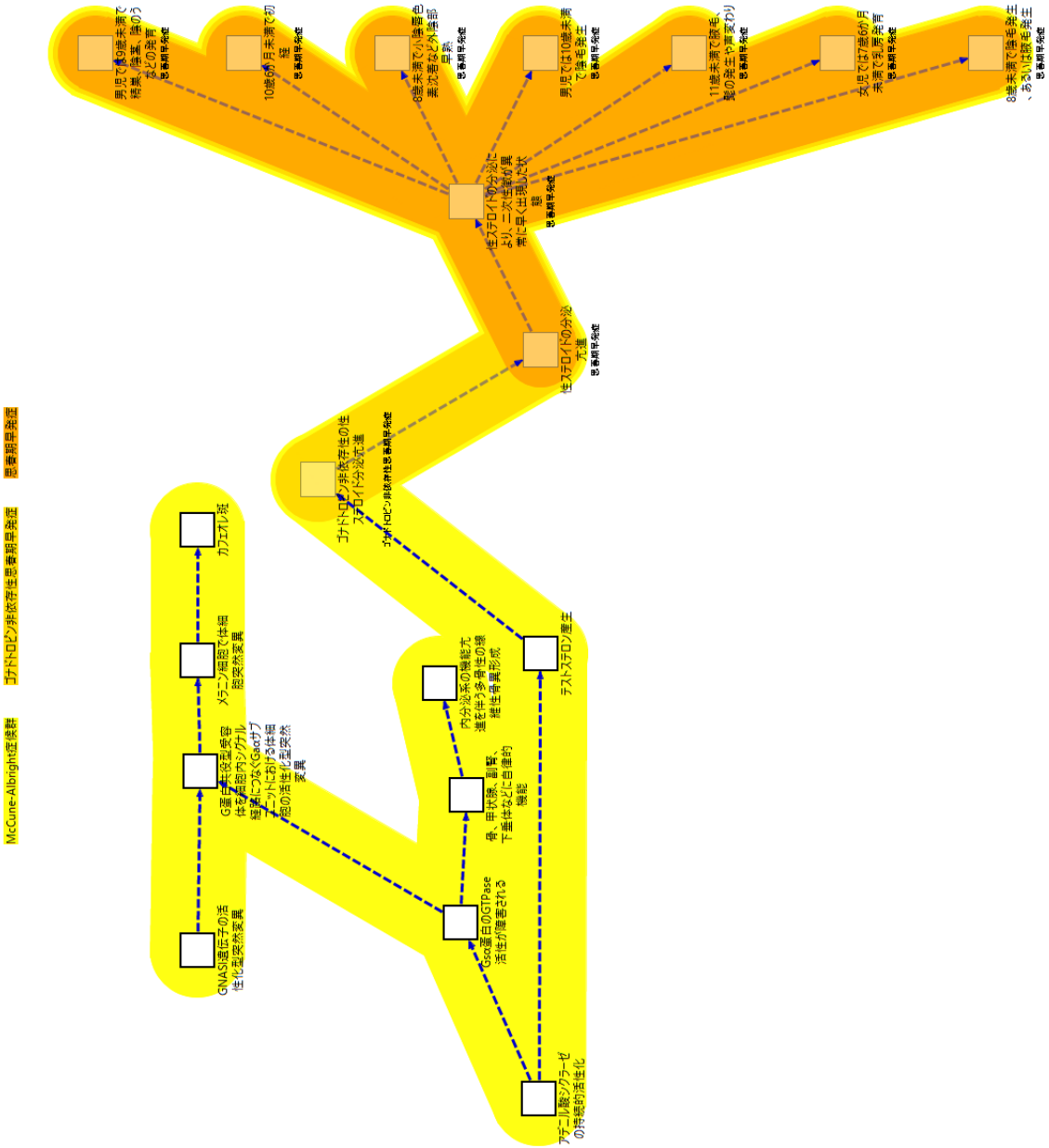

Figure 64. 糖尿病代謝内科:McCune-Albright 症候群

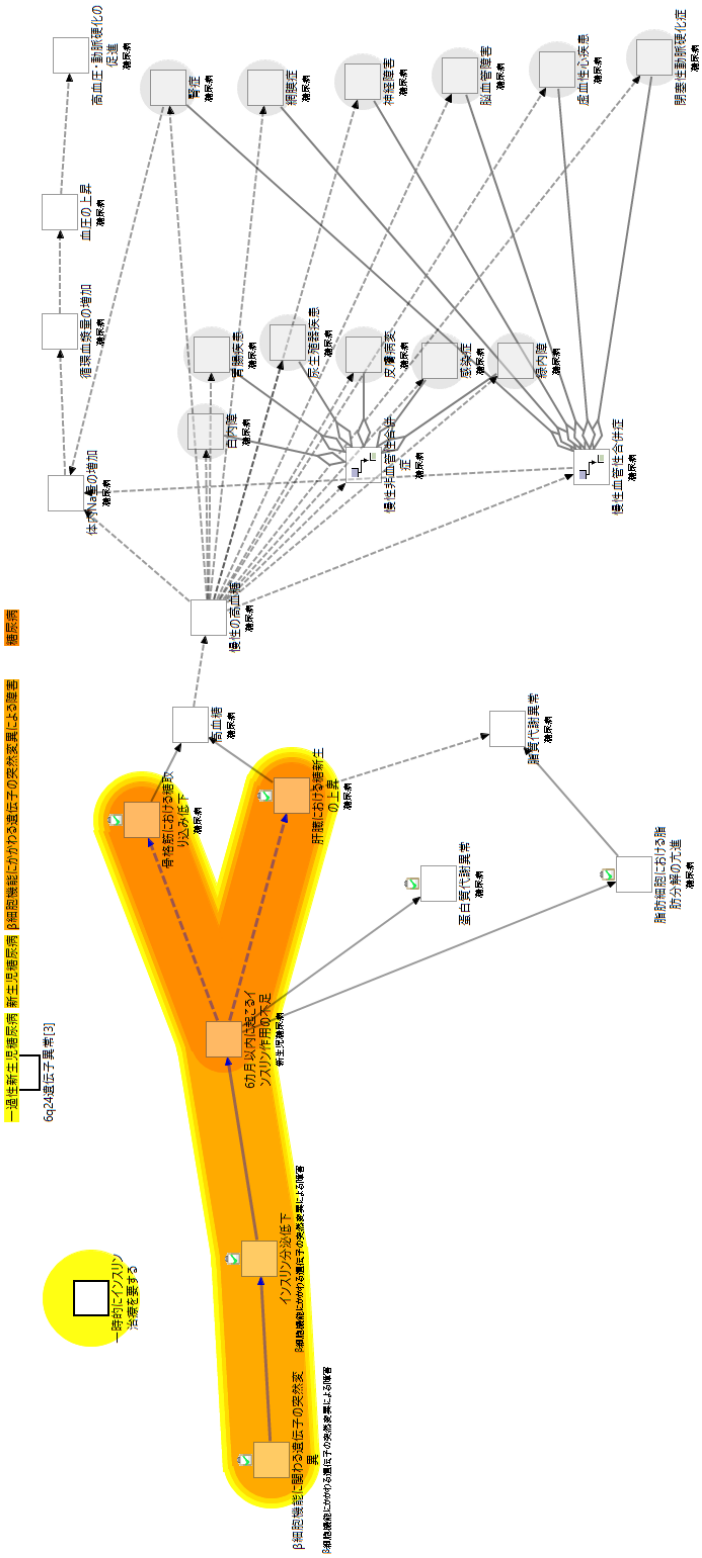

Figure 65. 糖尿病代謝内科:一過性新生児糖尿病

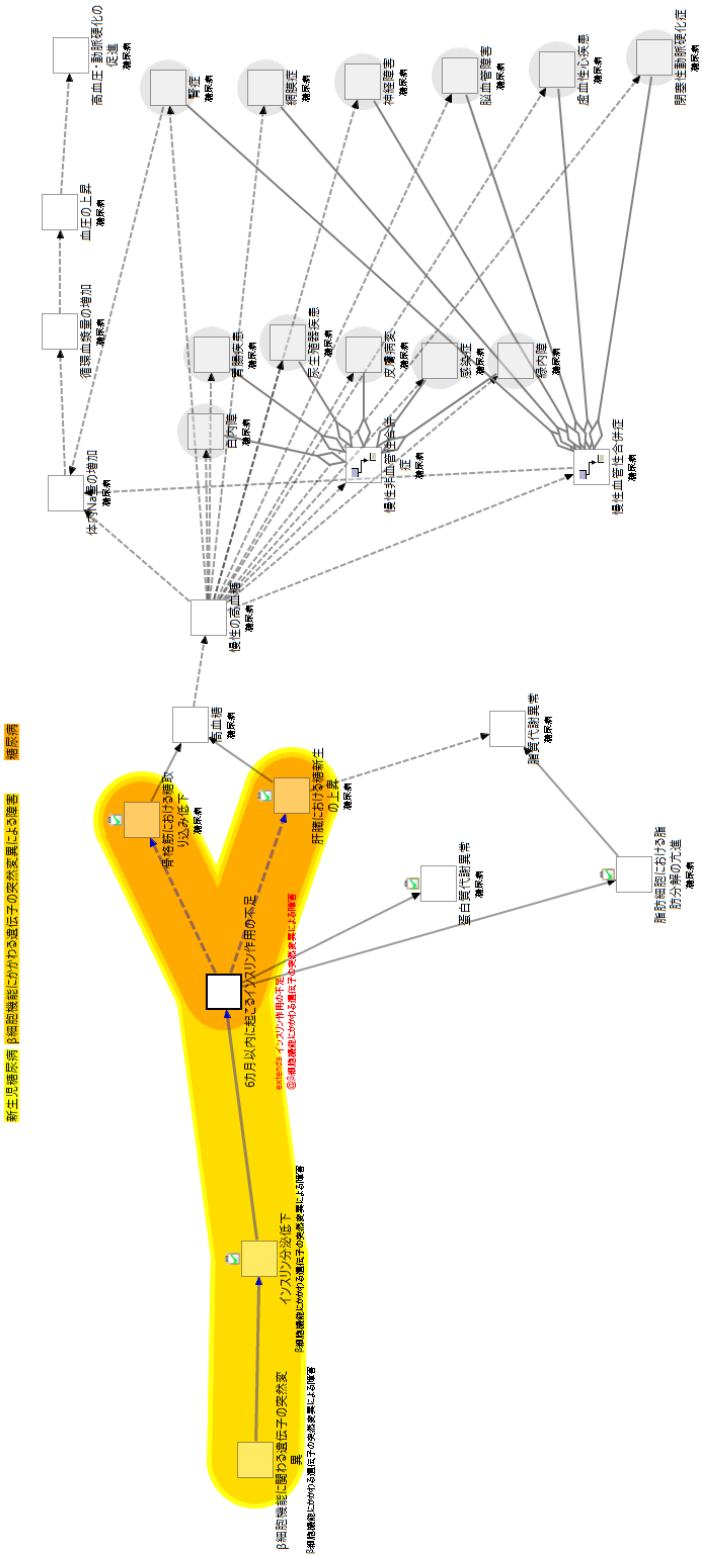

Figure 66. 糖尿病代謝内科:新生児糖尿病

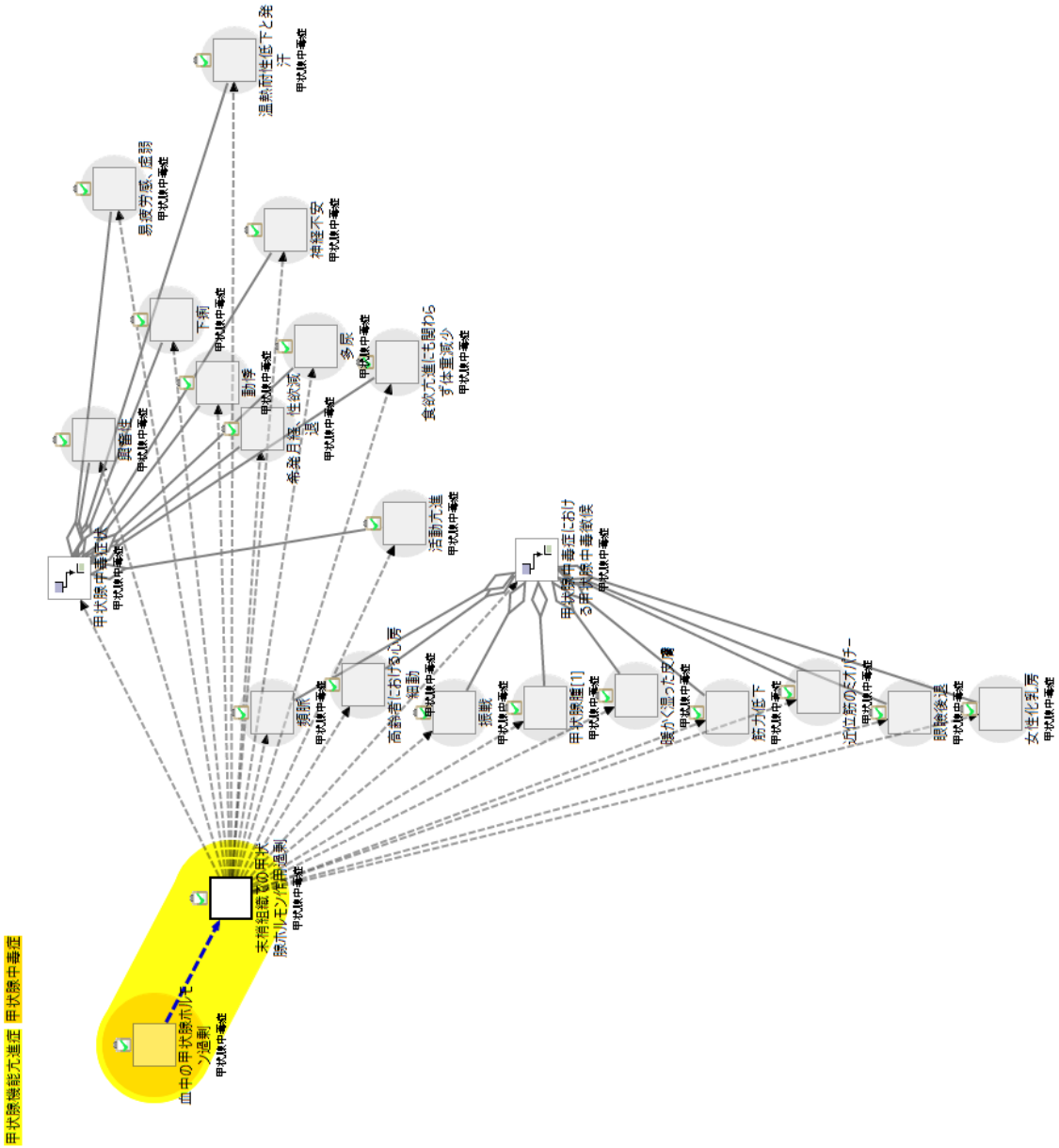
甲状腺機能亢進症 甲状腺中毒症
血中の甲状腺ホルモン過剰
甲状腺中毒症
末梢組織での甲状腺ホルモン作用過剰
甲状腺中毒症
甲状腺中毒症
甲状腺中毒症

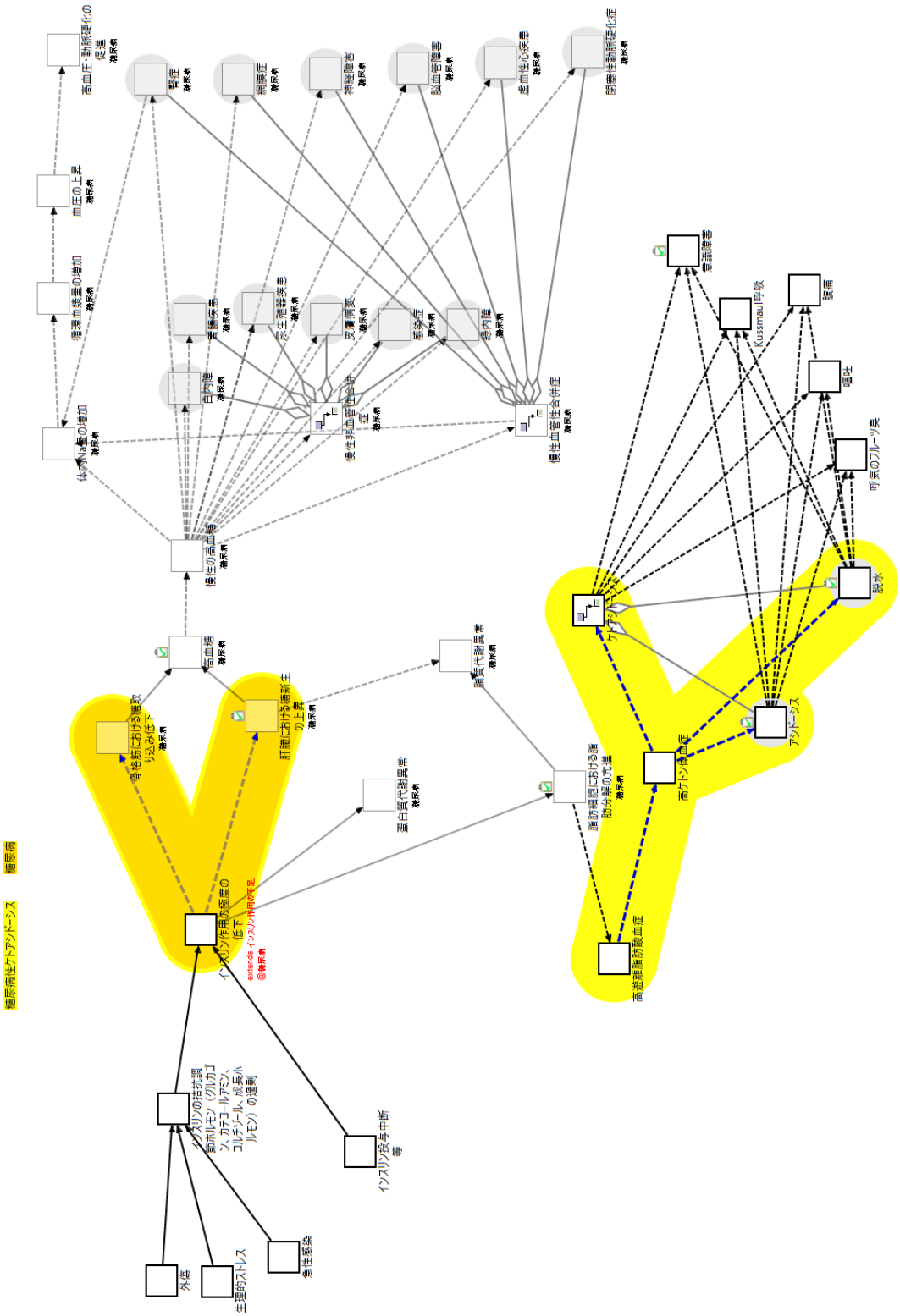

Figure 68. 糖尿病代謝内科:糖尿病性ケトアシドーシス

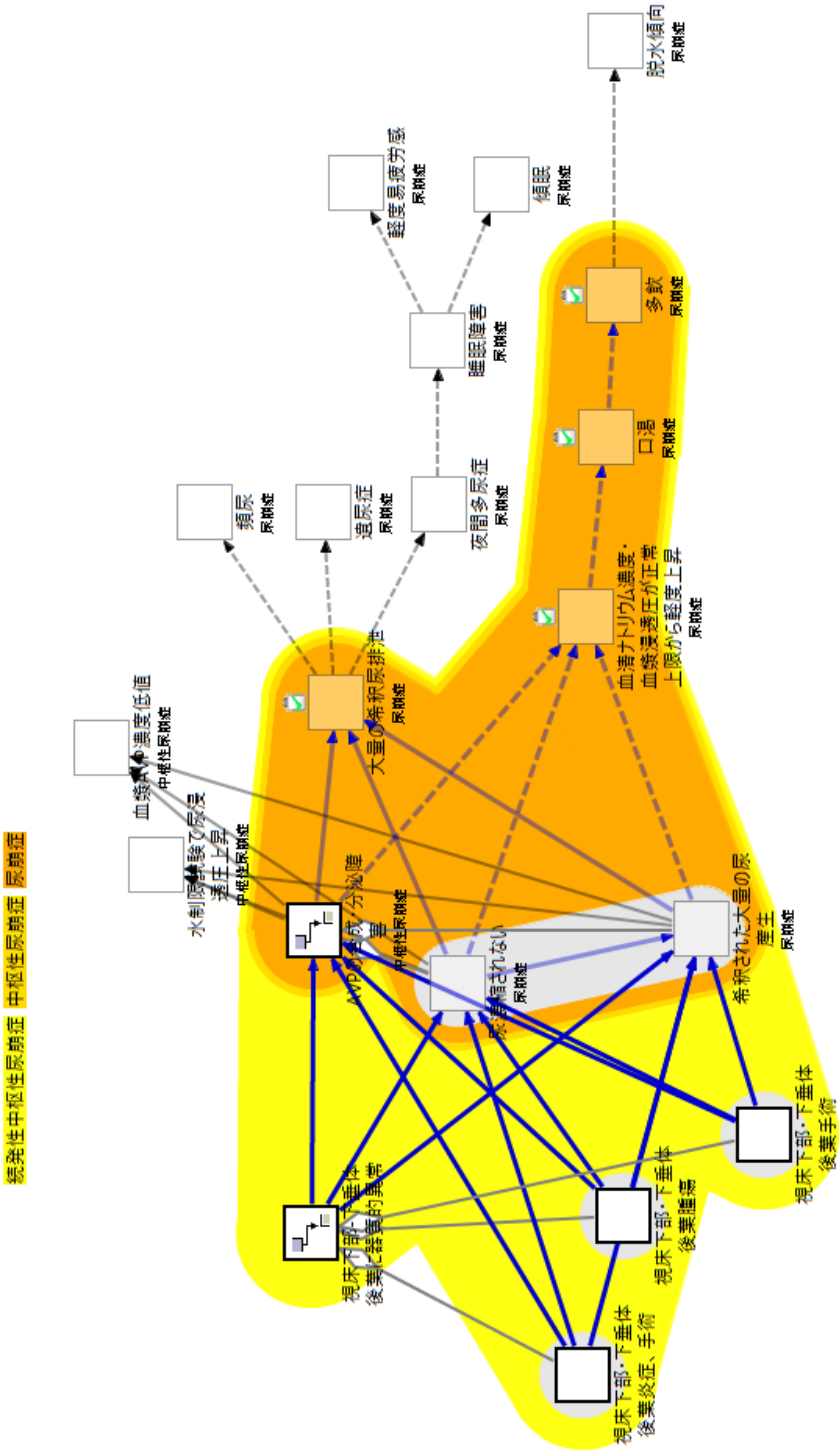

Figure 69. 糖尿病代謝内科:続発性中枢性尿崩症

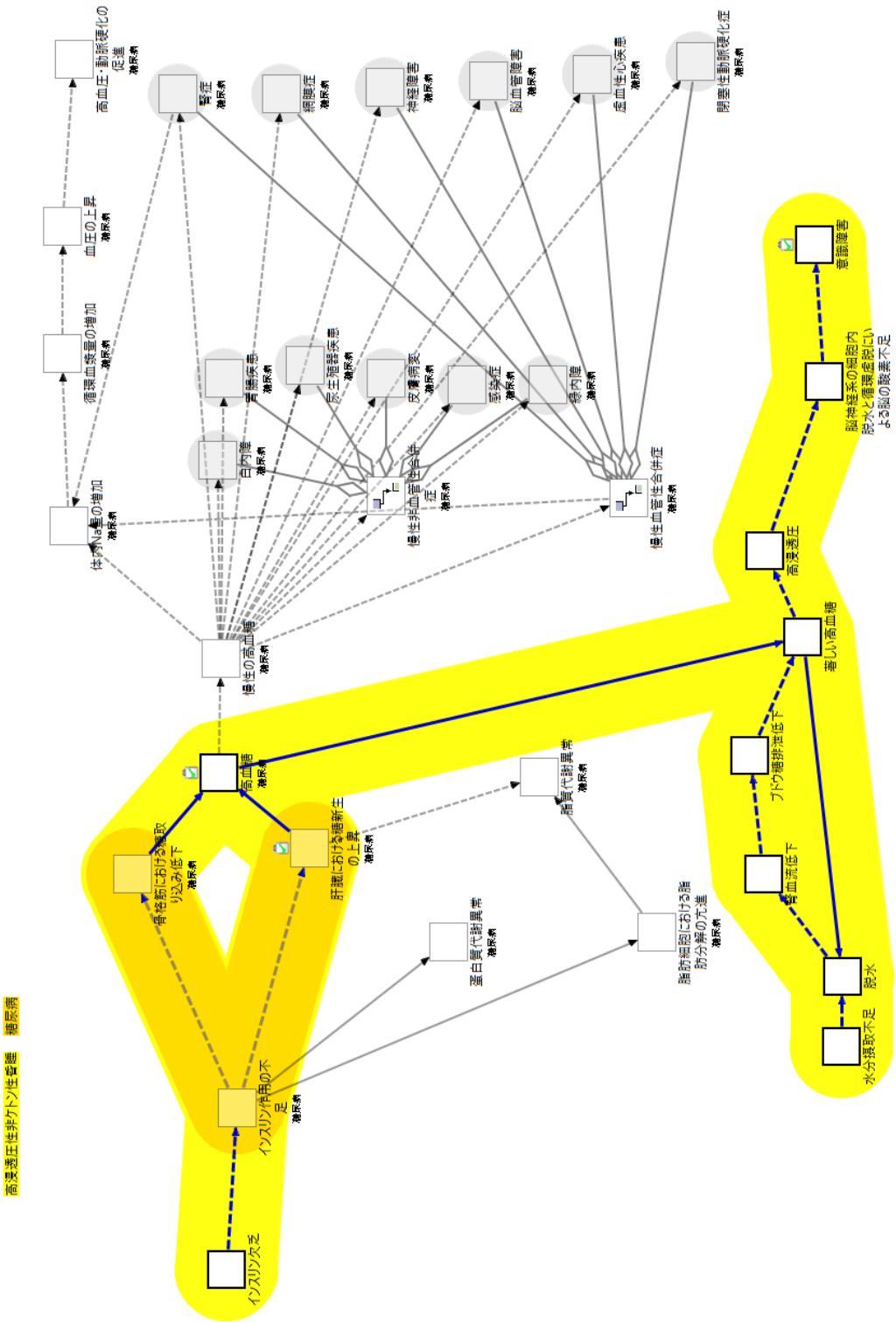

Figure 70. 糖尿病代謝内科:高浸透圧性非ケトン性昏睡